BEST DEVICES FOR SKIN TIGHTENING

David J. Goldberg, MD, JD
Skin laser & surgery specialists
Schweiger dermatology group
Icahn school of medicine at mt. sinai
New york, ny

DISCLOSURES

Research Grants: Cutera, Sofwave, Benev and BTL

Speakers Bureau: Cutera, Aerolase, Scientis, Sofwave, benev, btl, AMP

NON-INVASIVE BODY CONTOURING

- Face
- Body

NON-INVASIVE BODY CONTOURING

- Laser Resurfacing

Combined 1064nm 650usecond/ Superficial Erbium Laser: Reverse Approach

Before

4 Days After Treatment

RESULTS – PATIENT IN EARLY-40S

Before Treatment | Immediately After Treatment | Morning After Treatment | 5-Days Post Treatment

RESULTS – PATIENT IN EARLY-40S

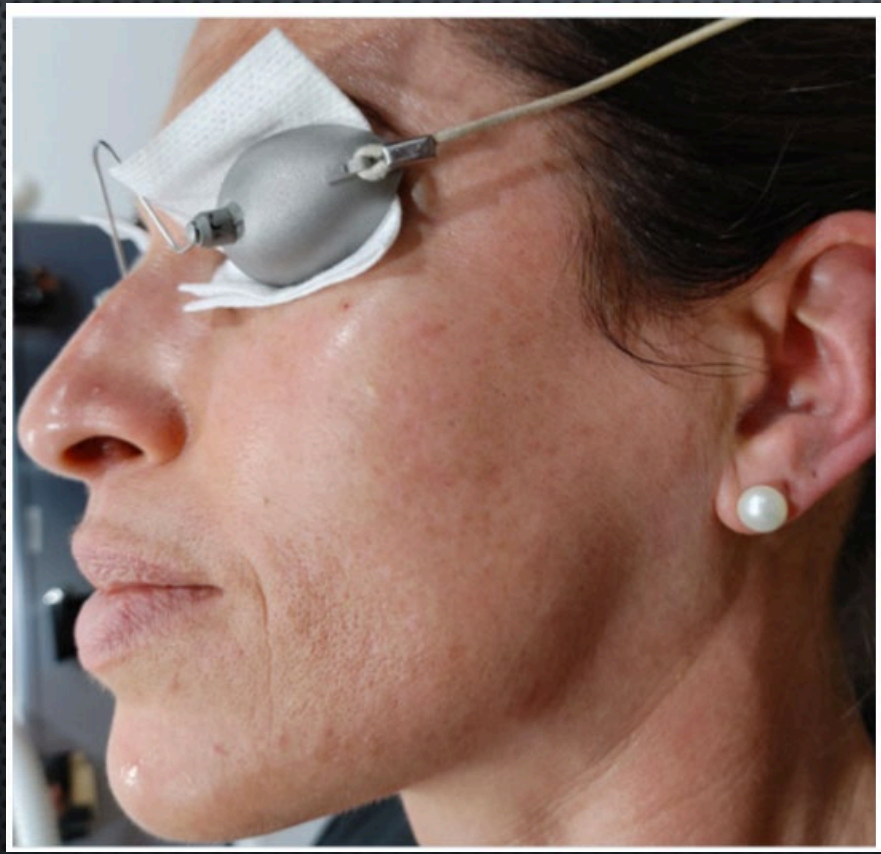

Before

5 Days Post Treatment

RADIOFREQUENCY

Evolution

1st Generation

2nd Generation

3rd Generation

1 Session

Before 1st treatment

4 weeks after 1st treatment

INDIBA®
revitalizing lives

Infraorbital Fat Pads

Treatment of Periorbital Wrinkles & Lower Eyelid Fat Herniation

Before and 3 months post 1 treatment.

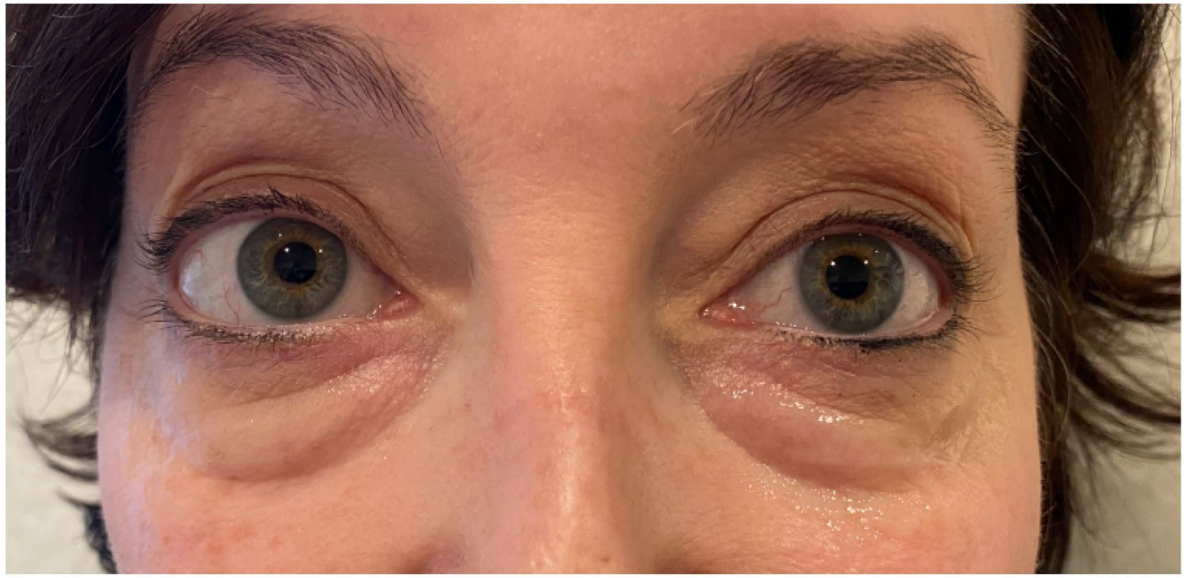

ADVANCES IN FOCUSED ULTRASOUND -FACIAL SKIN TIGHTENING

HIFU

- Coagulation pattern – pinpoint 1X1 mm columns are produced perpendicular to the skin surface
- U/S beams are emitted sequentially
- Separate transducers are used to treat at varying depths (1.5, 3.0, 4.5 mm) and each is performed in a separate treatment pass
- Need for real time ultrasound visualization to avoid deep tissue structures

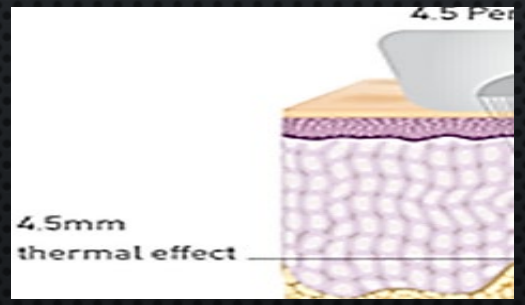

Parallel USB Technology

- Coagulation pattern – elongated cylinders 1.5 x 4 mm are produced parallel to the skin surface and centered at a depth of 1.5mm
- High volume coverage along skin tension vectors
  - 28% 2 passes
  - 43% 3 passes
- No need for real time ultrasound visualization

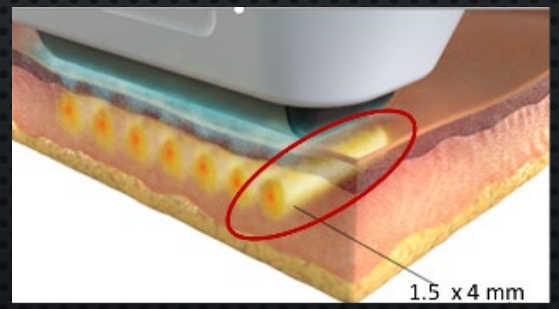

BASELINE

12 WEEKS FU. 2TX

Courtesy of Roy Geronemus, MD

BASELINE

1-MONTH FU

Hematoxylin & Eosin staining

Before and 10 months after one treatment

A

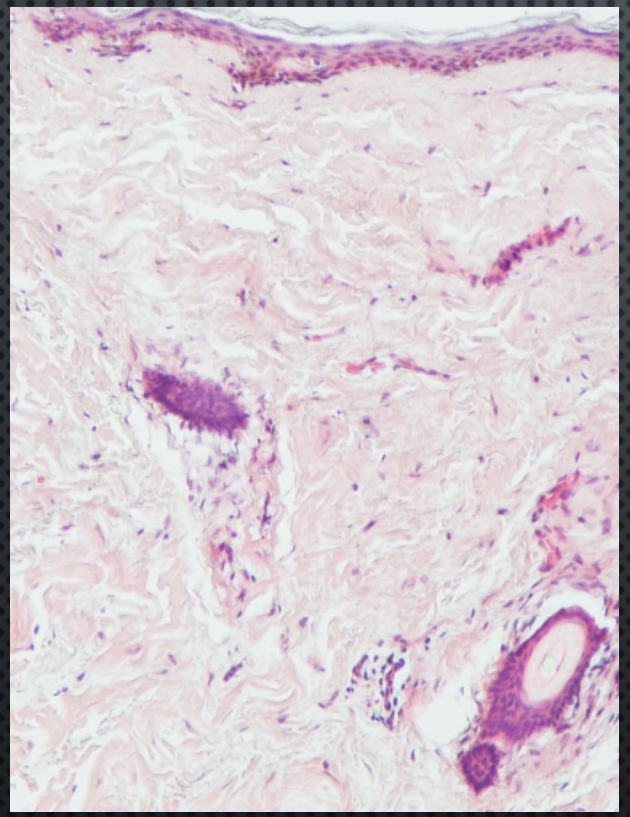

B

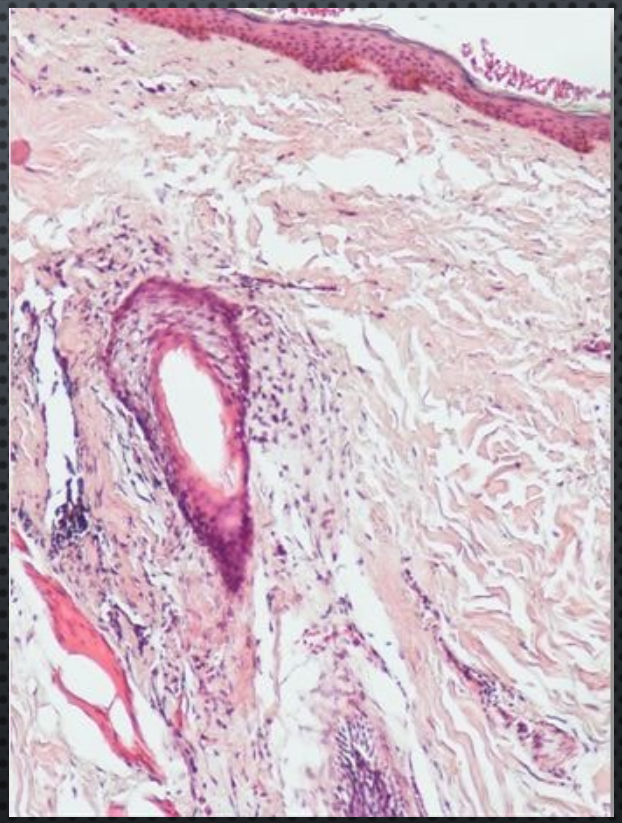

Skin biopsy revealed significant regenerated and increased dermal collagen fibers in the reticular dermis after treatment, x10 magnification. A (before treatment), B (after treatment). Note the unique parallel alignment and structural order of the fibers.

Dr. Virginia Benitez Roig

MASSON'S TRICHROME STAINING

BEFORE AND 10 MONTHS AFTER ONE TREATMENT

A

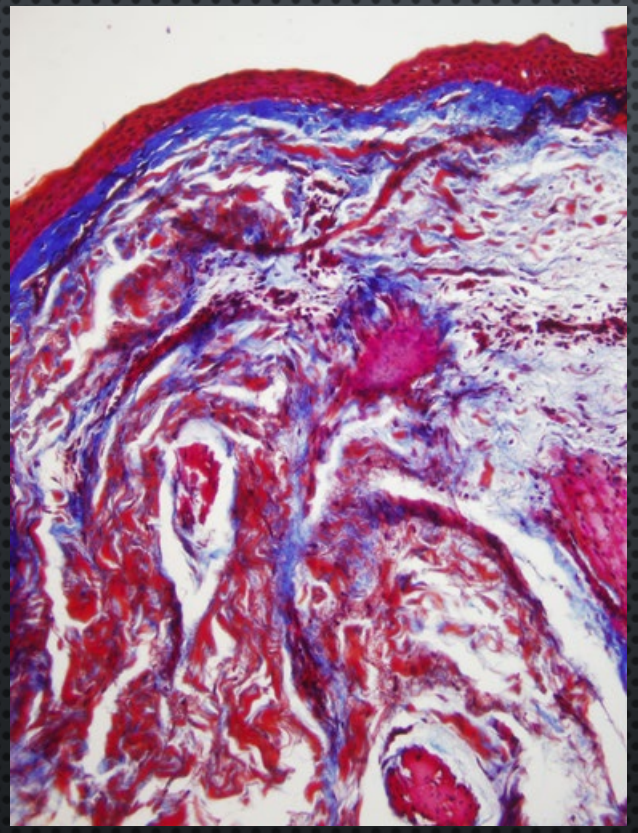

B

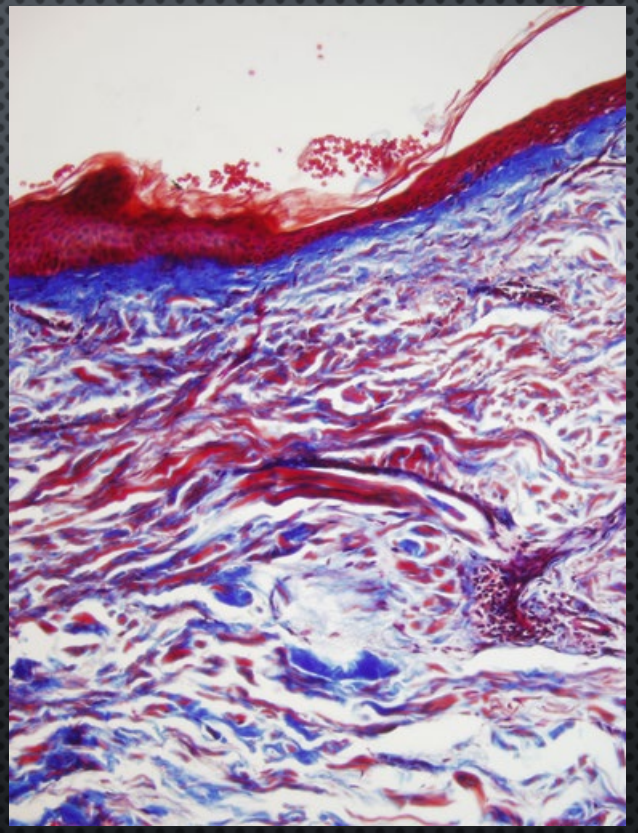

Skin biopsy revealed a significant increase of dermal collagen in the reticular dermis after treatment (x20 magnification. A: taken before treatment, B: taken 10 months after treatment)

Dr. Virginia Benitez Roig

Alcian Blue staining

Before and 10 months after one treatment

A

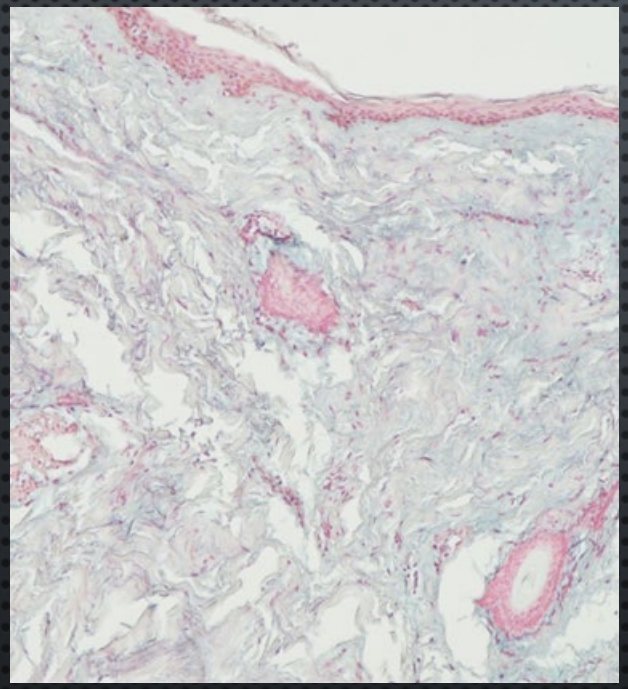

B

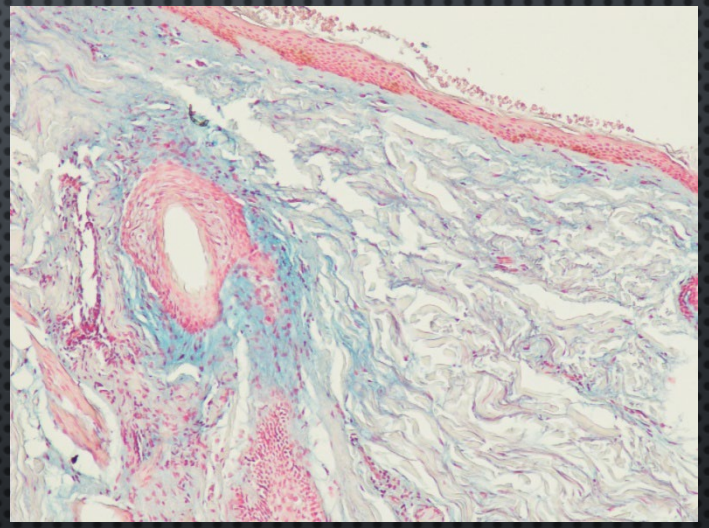

Alcian blue (AB) staining, which stains all types of GAGs, showed strong stain in whole extracellular spaces in dermis and dermal cells including fibroblasts and endothelial cells. (x10 magnification. A: taken before treatment, B: taken 10 months after treatment). Note the significant increase in connective tissue HA with unique alignment of connective tissue fibers and overall increase in dermal thickness

Dr. Virginia Benitez Roig

Clinical Study- Objectives and Methods-Our Study

Objective:

- Assess the safety and performance of Sofwave treatment for lift lax tissue on face areas (including lift the eyebrow and lift lax submental and neck tissue) and facial wrinkles reduction

Methods:

- Subjects underwent 2 treatments and were followed at 3 and 6 months post last treatment
- All subjects were treated on 3 subareas of the face: forehead and temples for eyebrow lift, submentum and neck for lax submental lift and the cheeks including perioral and chin for wrinkle reduction
- Optional –additional off-face areas may be treated
- Study investigator assessed the improvement and subjects reported their satisfaction
- Numerical Response Scale (NSR) was used to document subjects' comfort during the treatment
- Immediate responses and safety aspects were recorded throughout the study visits

Clinical Study: Results

Results:

- 10 subjects (8 females; 2 males) aged 48-71 years (mean ±std 61 ±8) were enrolled, treated of facial and completed the study
- 2 subjects were treated in addition on off-face areas (one on abdomen and one on upper arms)
- All three facial indications (all treated areas) were improved at 3-months follow-up
- At 6-months follow-up visit, the improvement rates remained high (90%) for all three indications (lift eyebrows (Area 1); facial wrinkles reduction (Area 2); lift lax submental and neck tissue(Area 3))
- Improvement was recorded also on off-face treated areas
- In similar, most of the subjects reported on satisfaction and willing to undergo additional treatments

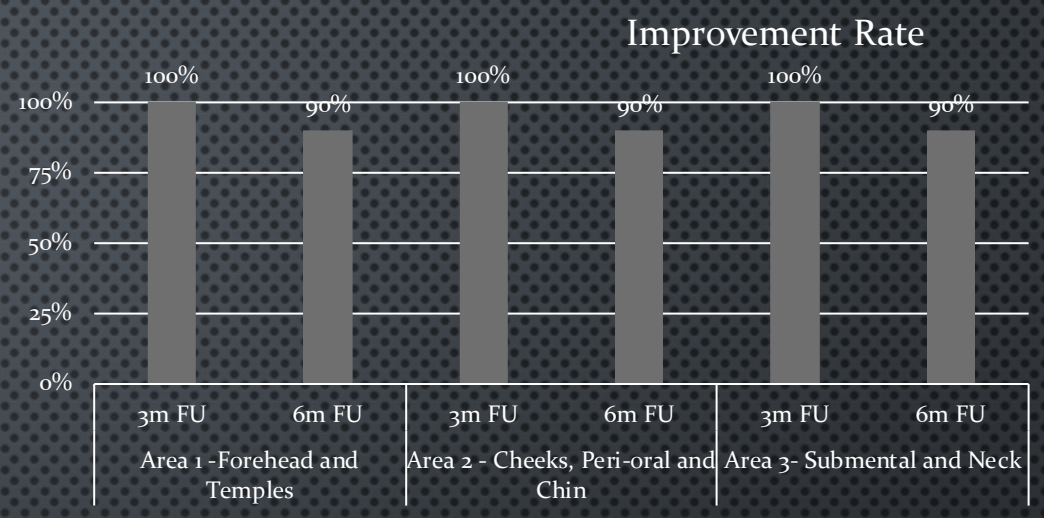

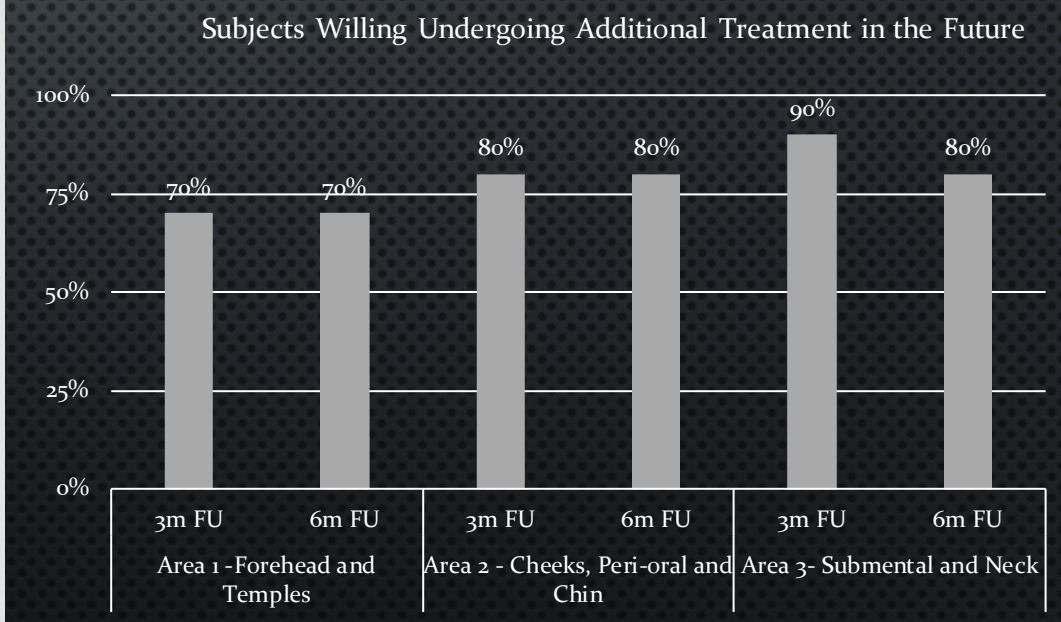

Clinical Study: Results

Results:

- Pain level was 4.6±1.6 on 0-10 scale (0=no pain; 10=worst pain)
- Tissue responses were limited to slight edema (90%), slight-moderate erythema (100%) and slight ulceration (10%). These effects resolved completely without medical intervention
- No adverse events were recorded during the study course

Conclusion:

- This new-generation ultrasound device was demonstrated to safely provide eyebrow lifting, lax submental and neck tissue lifting and facial wrinkles improvement.

Before

3m FU

6m FU

Photos Courtesy of David Goldberg, MD

405 K-L

Before

3m FU

6m FU

Photos Courtesy of David Goldberg, MD

405 K-L

Before

3m FU

6m FU

Photos Courtesy of David Goldberg, MD

Acne Scars

PRE-TREATMENT

6 months after 2 treatments

Pre-tx

3 months FU

Pre-tx

3 months FU

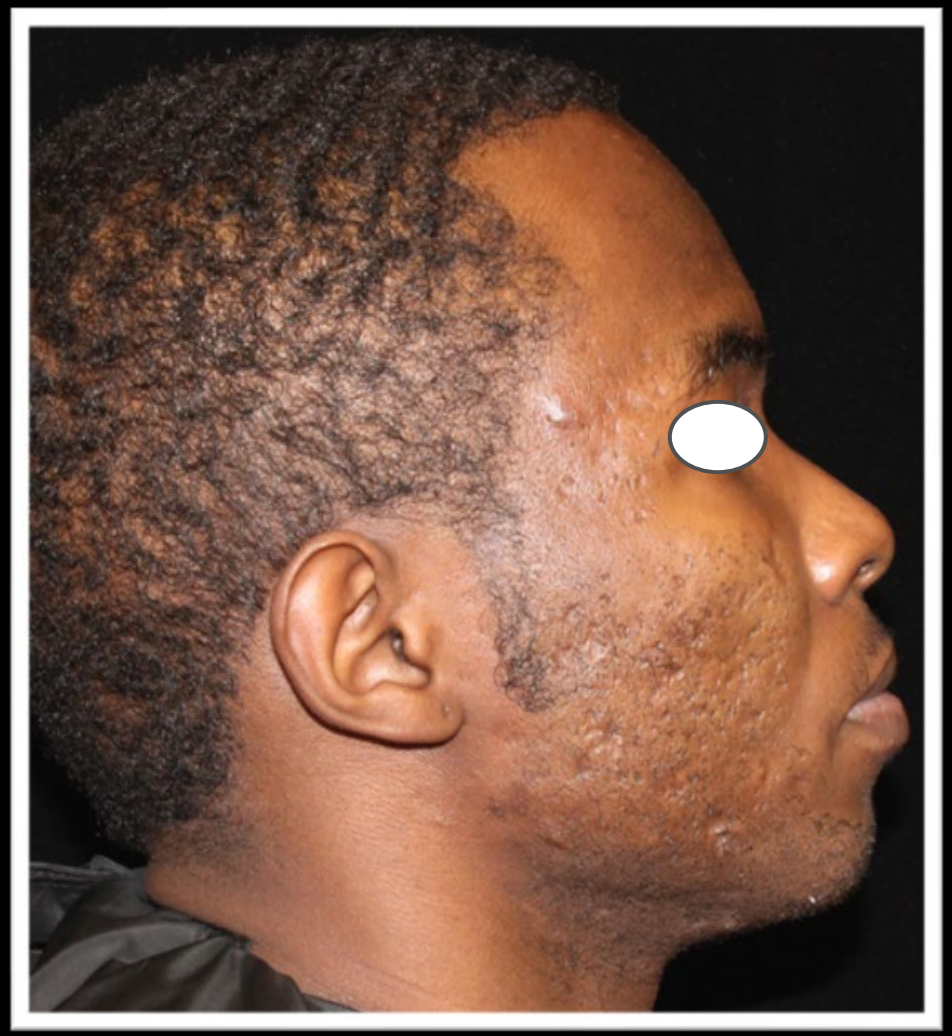

Pre-tx

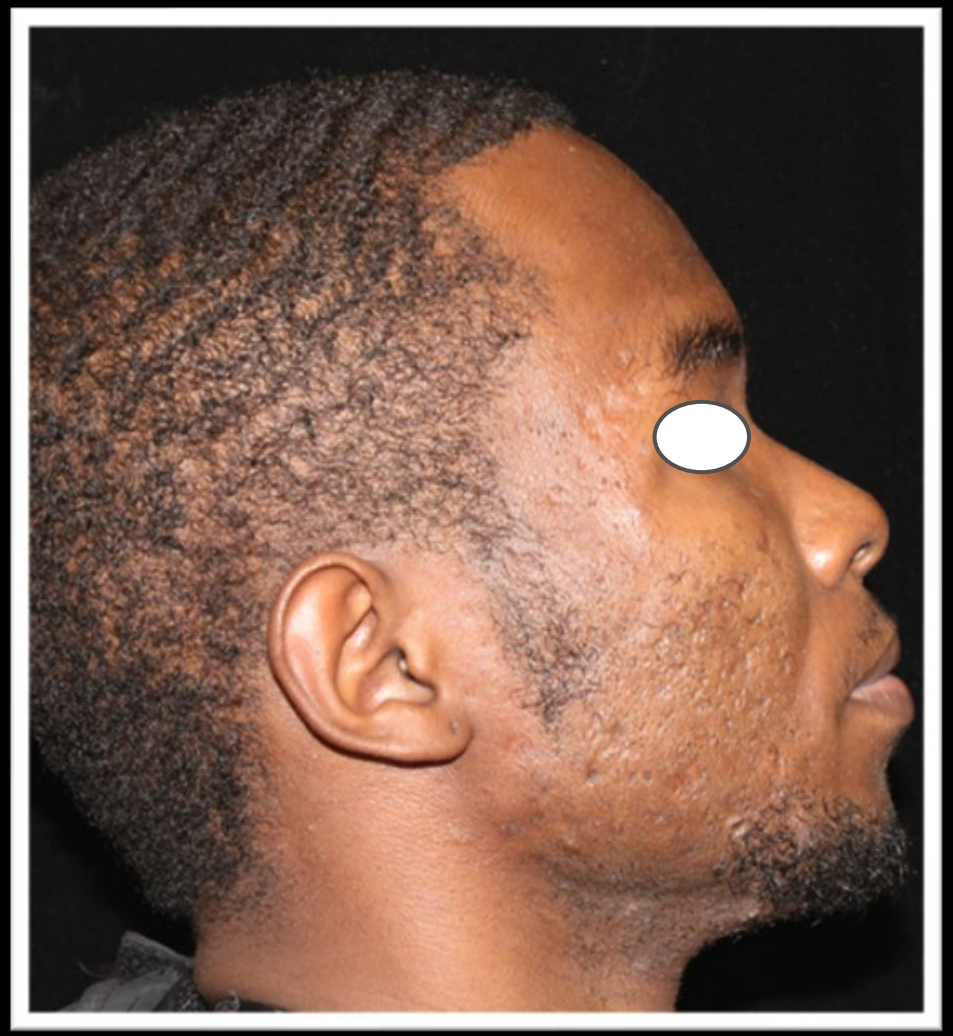

Post 2 treatments

EXOSOME SCIENCE AND REGENERATIVE AESTHETICS

POTENTIAL OF ADIPOSE DERIVED STEM CELL EXOSOMES IN SKIN RELATED APPLICATION

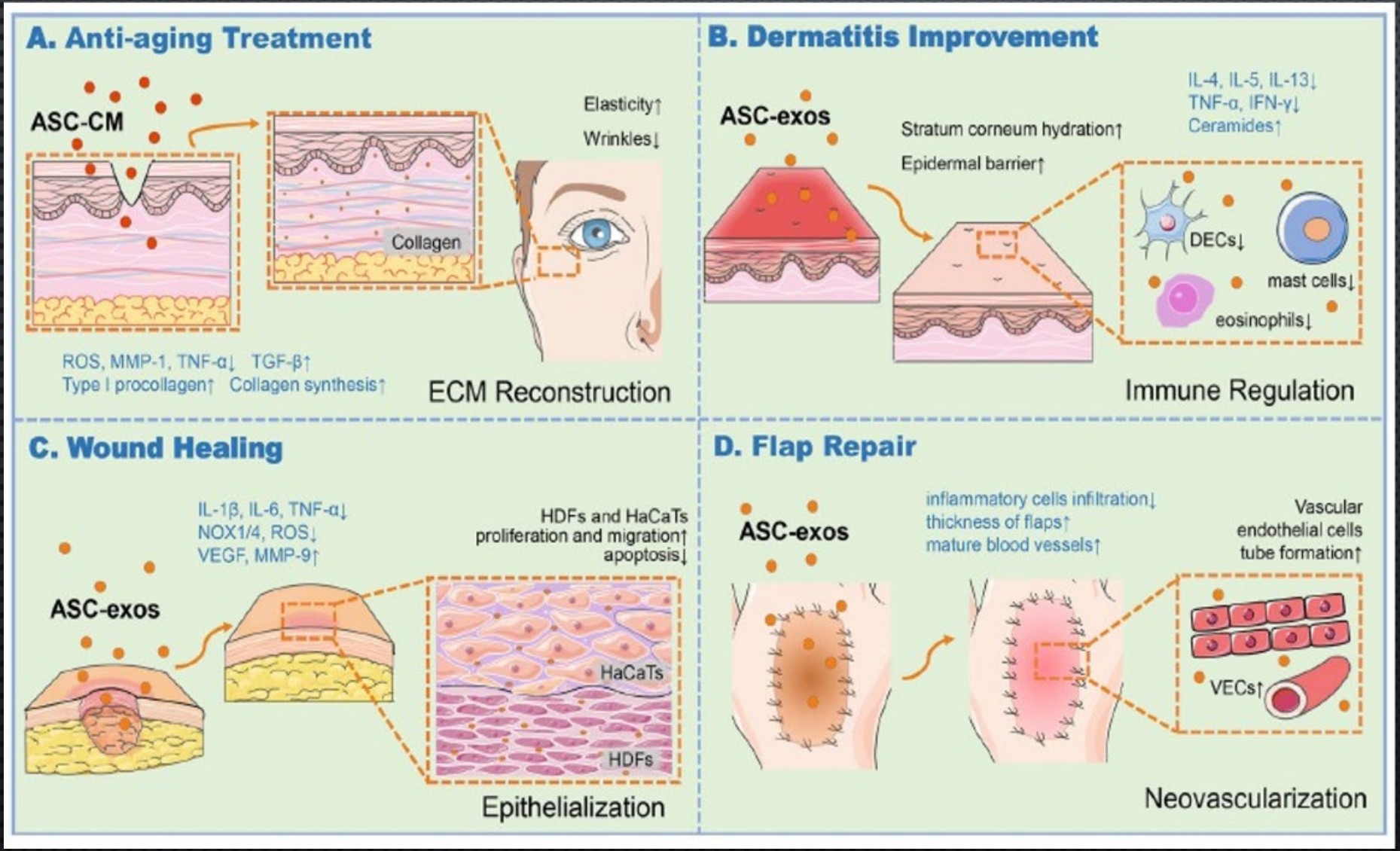

Plasma Pen 24 Hour Post

48 Hours Post

POST-PROCEDURE FOR ENHANCED ANTI-AGING EFFECTS

Before treatment

After treatment

- Generally improved aesthetic post-application of Professional Serum.
- Plumper, tighter skin.
- Decreased naso-labial folds
- Improved complexion and improved appearance around eyes.

Treatment: Micro-needling treatment for treatment of acne scarring

Application:

- Left Hand image – Immediately post treatment without serum
- Right hand image – 5-10 minutes post application

Results:

- Reduced Redness
- Reduced Swelling

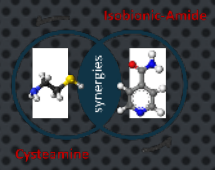

Synergistic effect: Cysteamine with Isobionic-Amide

Cysteamine 7%

Cysteamine reduces melanin production in the melanogenesis pathway at multiple locations

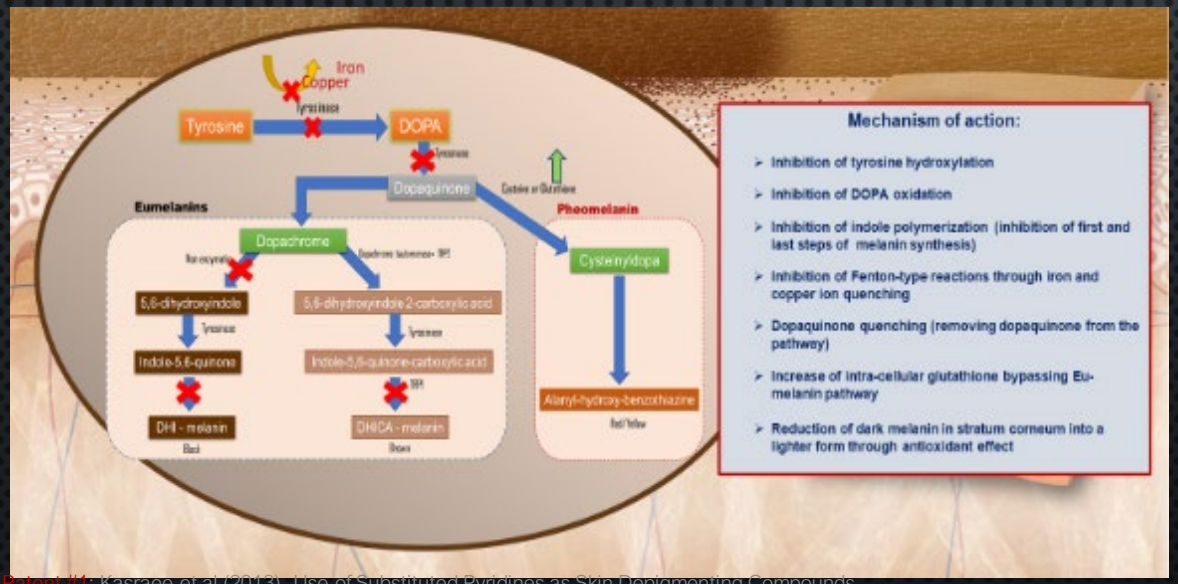

Isobionic-Amide

Isobionic-Amide reduces melanosomal transfer

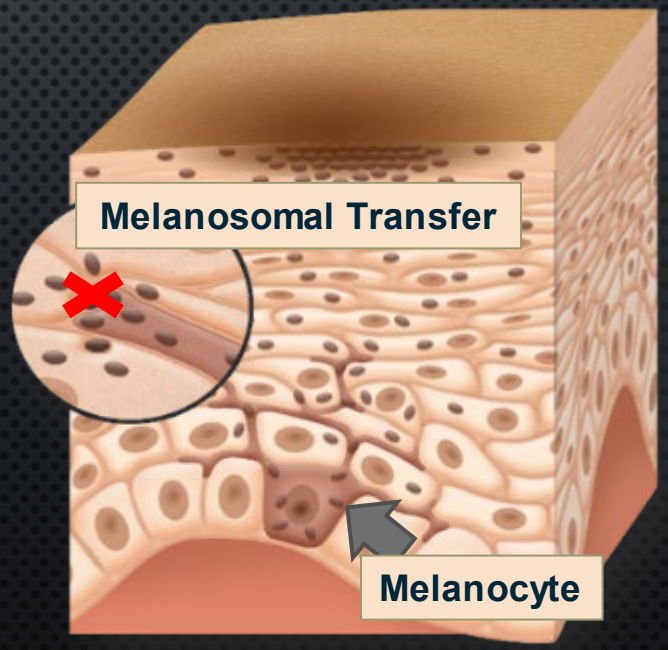

(1) Patent #1: Kasraee et al (2013). Use of Substituted Pyridines as Skin Depigmenting Compounds
(2) Experimental data on melanosomal transfer, melagenesis inhibition & melanin pigment lightening (ongoing experimental studies)

ADIPOSE STEM CELL MATRIX
NEXT GENERATION FILLER

FROM DONOR TO RECIPIENT

Whole adipose tissue depiction:

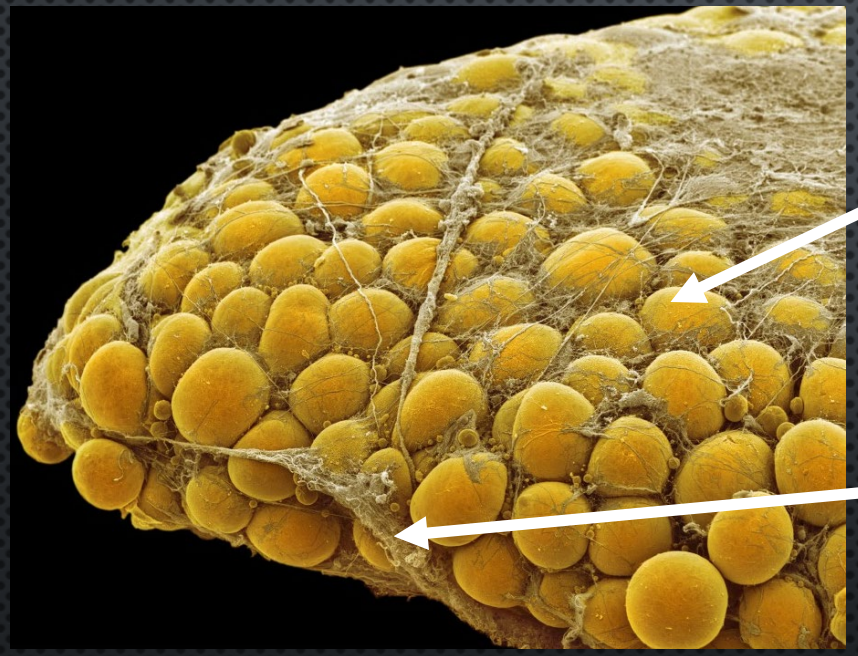

Image via www.lipofilling.com

Adipose Cells: Adipocytes

Adipose ECM (eventually Renuva™)

Human adipose H&E:

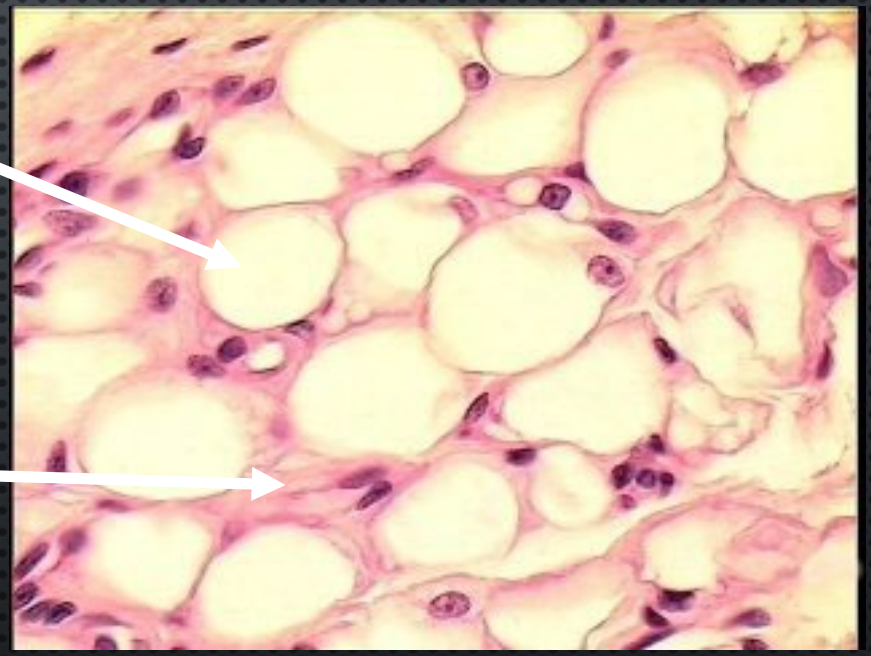

Image via academic.pgcc.edu

"In Vivo" Study in Athymic Mouse

Renuva™ injected subcutaneously in athymic mice supports host cell infiltration, angiogenesis and adipogenesis

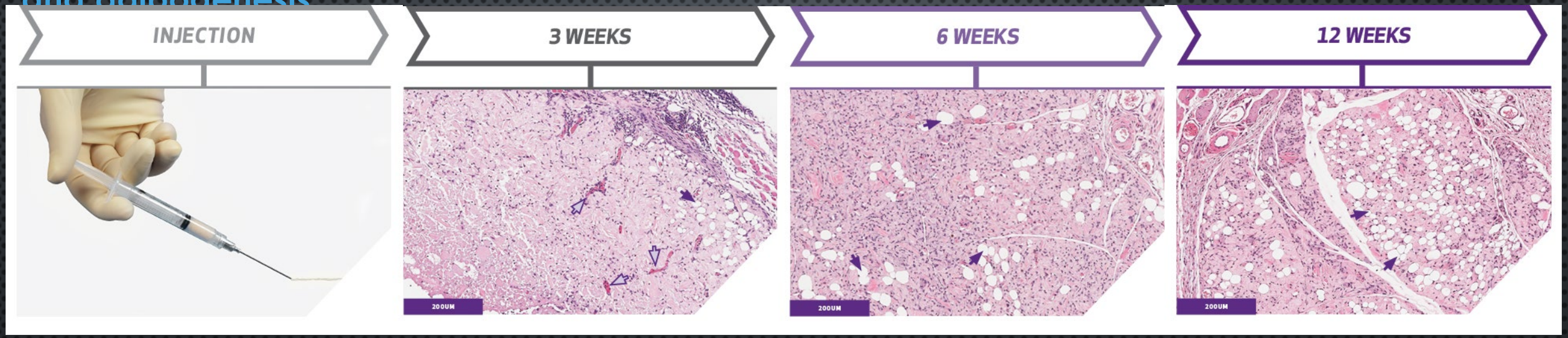

Adipose tissue injected

Minimal adipose tissue infiltration (solid arrows) along the margins of the implant and neovascularization (outlined arrows)

Mild adipose tissue infiltration in the organized implant (arrows indicate adipocytes)

Increased adipose tissue infiltration in the organized implant (arrows indicate adipocytes)

CLINICAL DATA

Temple Study

- 10 Patients, 4 sites (Dr. Gold, Dr. Kinney, Dr. Kaminer, Dr. Rohrich
- Option for re-injection of the site is included in the protocol

Primary Objective: Evaluate retention of Renuva over 24 weeks following injection in patients with bilateral atrophic temples

Secondary Objectives: Evaluate well-being/adverse events over 24 weeks following injection; histological evaluation of injection site via biopsy at 8 weeks

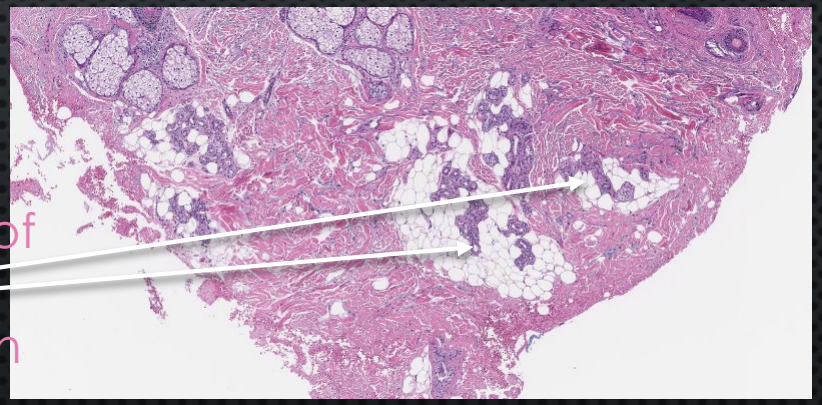

Pockets of adipose formation

CLINICAL STUDIES

Temple Study

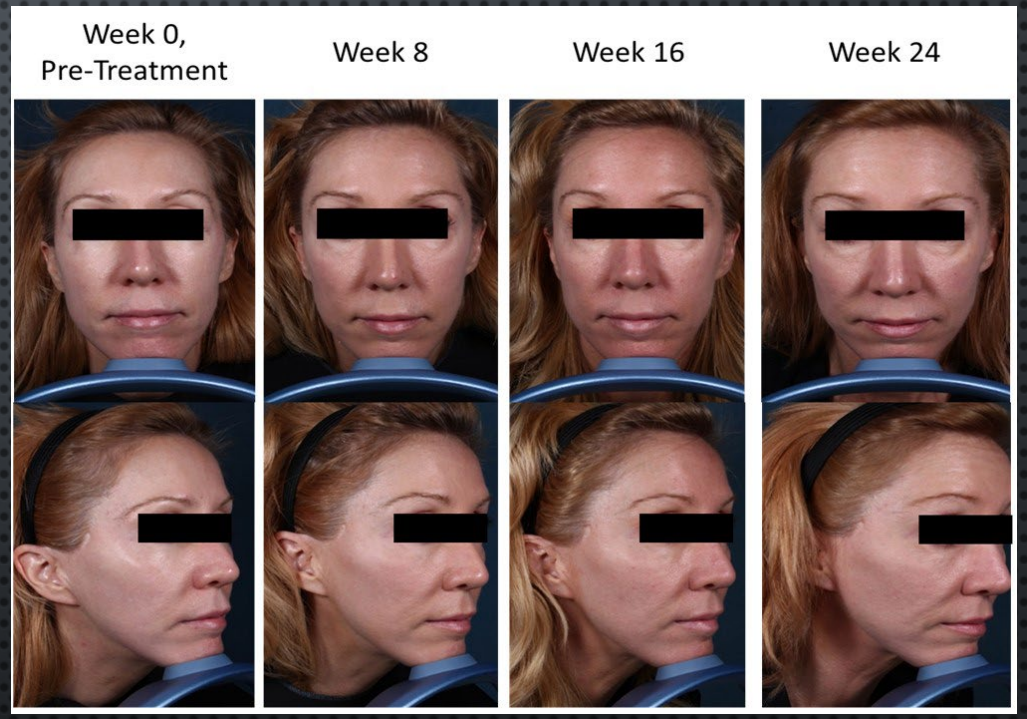

CLINICAL DATA

Temple Study

Results:

- safe and well-tolerated
  - Low complications; zero at 4 weeks
  - Achieve aesthetic correction; not over-correction
- Adipogenesis observed
- Retention at least 6mos

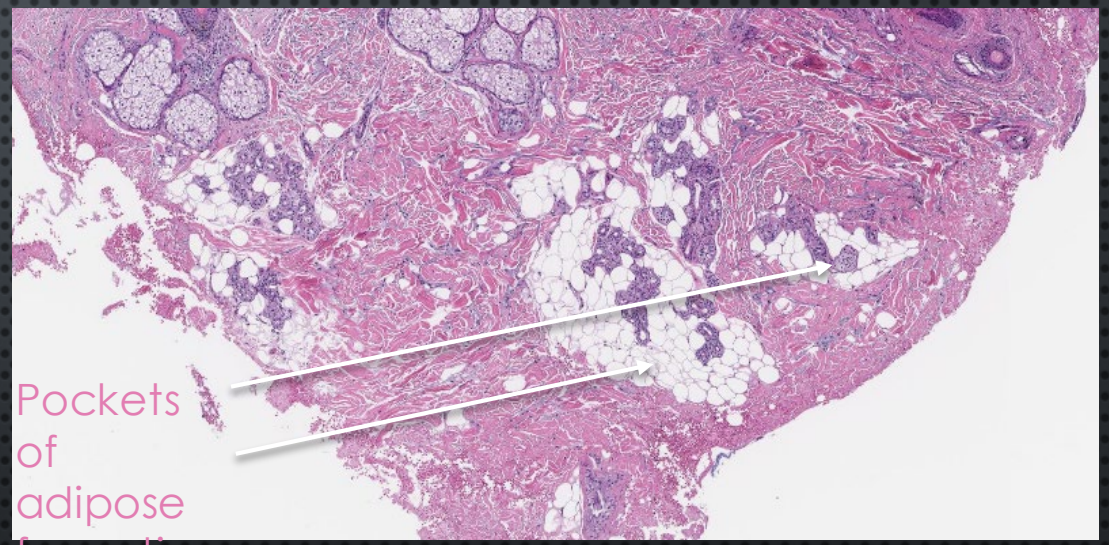

TREATING NFL VOLUME DEFICIT

Research Program

Schweiger Dermatology-Hackensack

STUDY DESIGN

- **Primary Objectives**:
  - Evaluate clinical safety & efficacy of the treatment of nasolabial folds (NLFs)
  - Assess improvement in the NLF appearance (Wrinkle Assessment Score-WAS)
  - Report any adverse events
  - Examine biopsy with histological imaging

Study Design:

- Prospective, single site
- n=10 patients
- Follow-up: 30, 60, 90 & 180 days
- Metrics: 2D photography of treated area, change in WA

VOLUME IMPROVEMENT IN NLFS AT 6 MONTHS

Time	Investigator	Subject
180 Days	+1	+1.5

Case 1 at 180 days Post-Treatment

Pre-treatment

Post-treatment Day 180

Investigator WAS	Subject WAS
+1	+1.5

- Volume correction in the NLFs
- Softer skin appearance

180 days Post-Treatment

Pre-treatment

Post-treatment Day 180

Investigator WAS	Subject WAS
+1	+0.5

- Volume correction in the NLFs
- Softer skin appearance

Presence of Adipocytes within Allograft Scaffold

Day 180

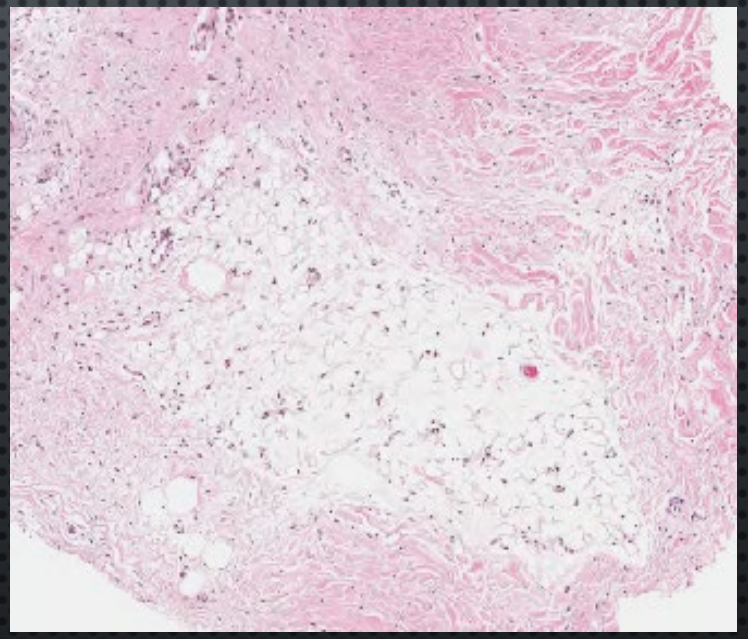

Collagen Type I and III at Day 180

Collagen Type I

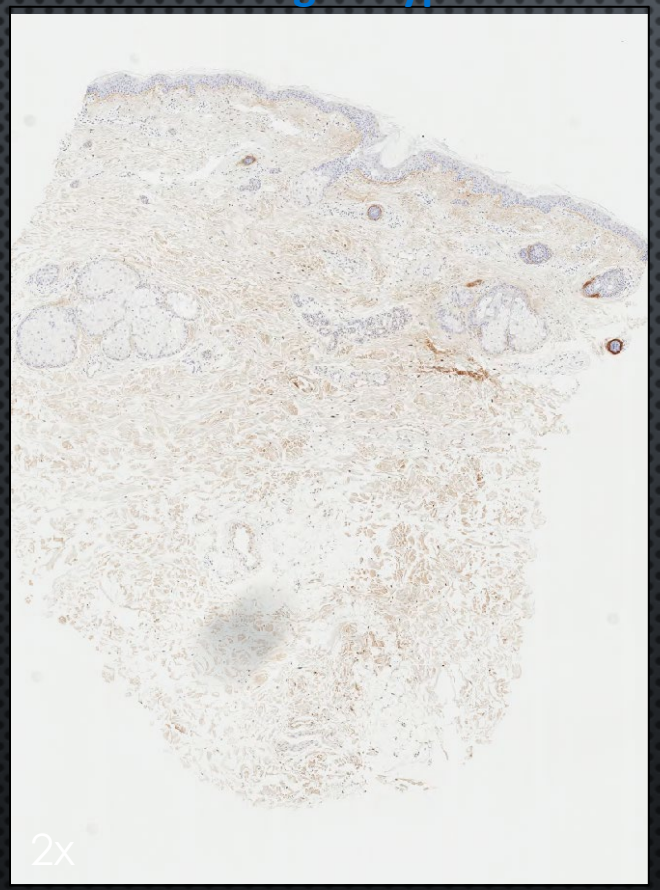

Collagen Type III

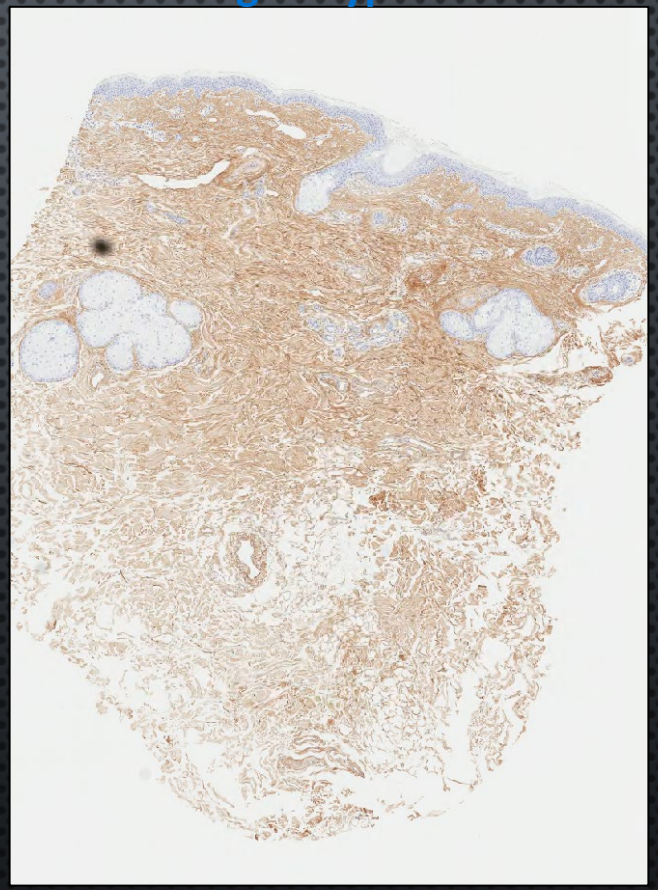

NASOLABIAL FOLDS

PRE-TREATMENT

180-DAY FOLLOW-UP

NASOLABIAL FOLDS

Pre-Treatment

180-Day Follow-Up

KEY STUDY FINDINGS

- Average injection volume 0.9±0.3 cc
- Minor adverse events (mild redness) resolved within 4±4 days
- 80% positive responders with Renuva treatment in NFL
- Both investigator and subject WAS positive responders were 80% at 6 months
- Presence of adipocytes and new collagen formation observed within allograft

- Face
- Body

NON-INVASIVE BODY SHAPING TECHNOLOGIES

RADIOFREQUENCY

CRYOLIPOLYSIS

ULTRASOUND

LASERS

- Technologies based on **controlled cooling or heating** (localized tissue hyper/hypothermia)
- Primarily **address** skin and/orsubcutaneous **fat**
- **HIFEM improves muscle tone/size**

COMBINED HIFEM/RF FOR NON-INVASIVE BODY CONTOURING

THE FIRST OF ITS KIND
SYNCHRODE RF™ ELECTRODE

A patented concept of combined application of RF heating and magnetic fields using electrodes made of hundreds of mutually interacting (synchronized**)** **interspaced segments.**

It is the **only applicator in the world** that can **emit RF heating and high intensity magnetic fields** at the same time.

STUDY DESIGN

- Three 30-minute abdominal treatments once a week
- Five patients in two groups:

ACTIVE TREATMENT (4 subjects)	SHAM TREATMENT (1 subject)
Age: 51.50±6.35 years	**Age:** 57 years,
BMI: 22.59±3.21 kg/m^2	**BMI:** 23.60 kg/m^2
HIFEM: Maximum tolerable intensity	**HIFEM:** 5% of device‘s output
RF: Maximum tolerable intensity	**RF:** 5% of device‘s output

- Evaluation baseline, after the last treatment, at 1W and 1M follow-ups
- Adverse events were monitored

RESULTS: FAT TISSUE HISTOLOGY

1 MONTH POST-TREATMENT

- Ruptured membranes in some adipocytes, no necrosis is present
- Destructive fragmentation of nuclei resulting from pyknosis (arrow)

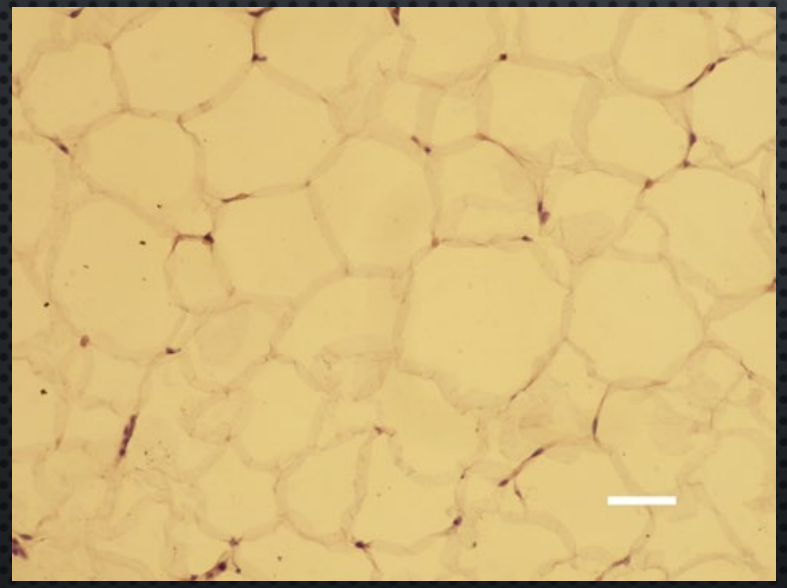

Control, 1 month

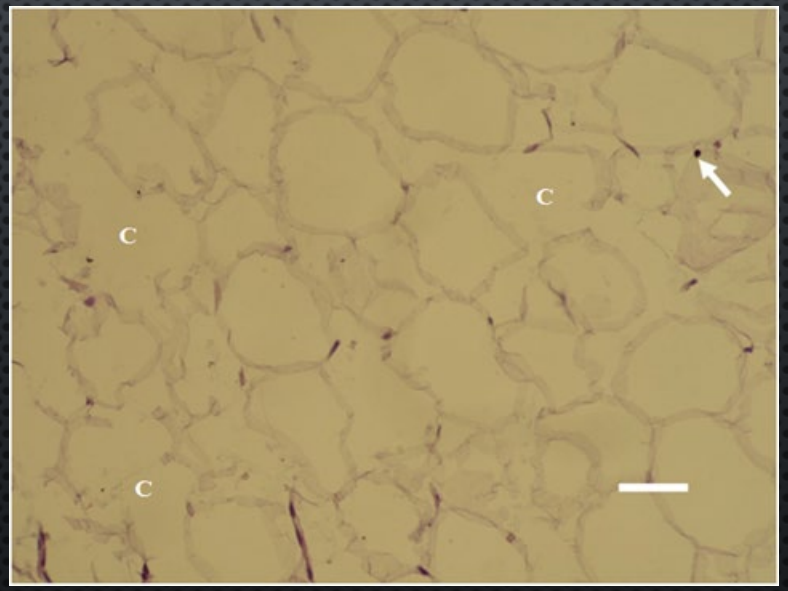

Active treatment, 1 month, μm

RESULTS: ADIPOCYTES SIZE

•

•**Significant (P<0.05) decrease in adipocytes Area; Control** subject showed **no change** over time

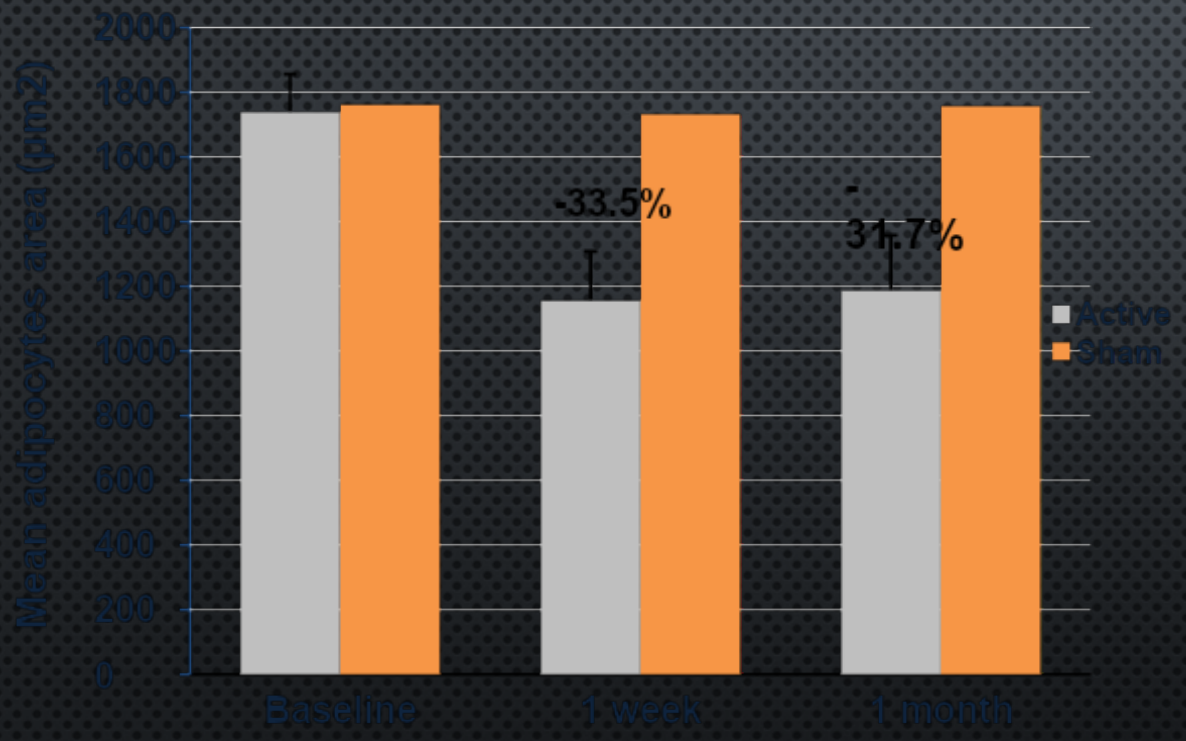

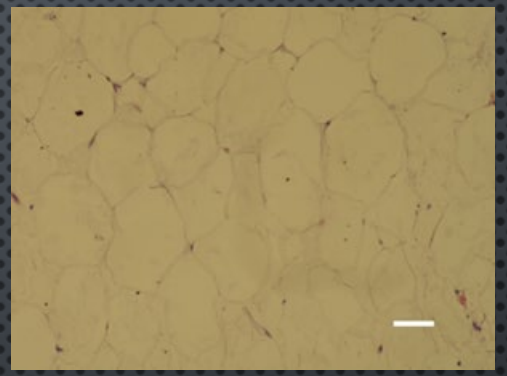

Baseline, bar = 40 µm

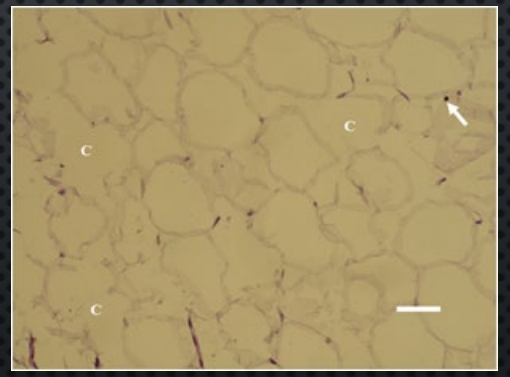

1 month, bar = 40 µm

RESULTS: DIGITAL PHOTOGRAPHS

Patient digital photographs (57 years, 22.98 kg/m^2) showing the improved body contour

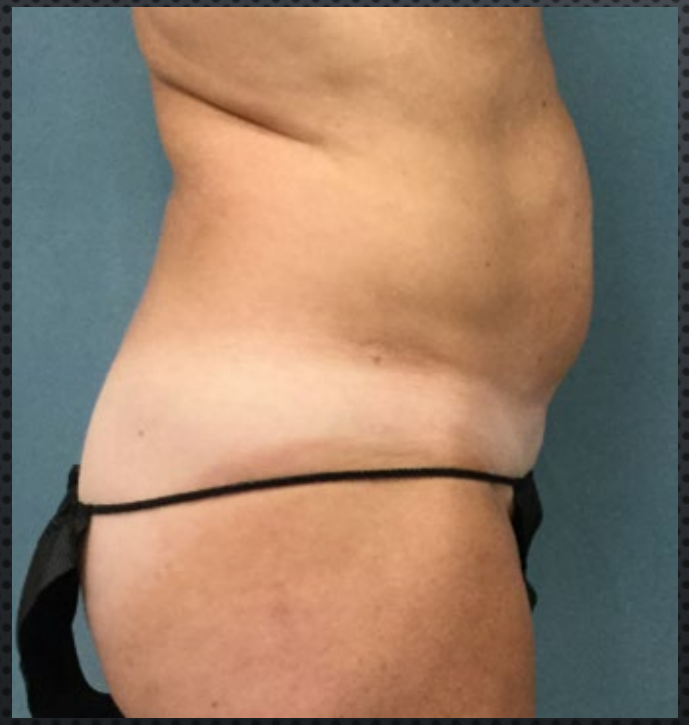

BASELINE

AFTER 1 MONTH

Immunochemistry :Collagen, membranes and healthy nuclei are **blue**; Caspase-3 nuclei are **brown**

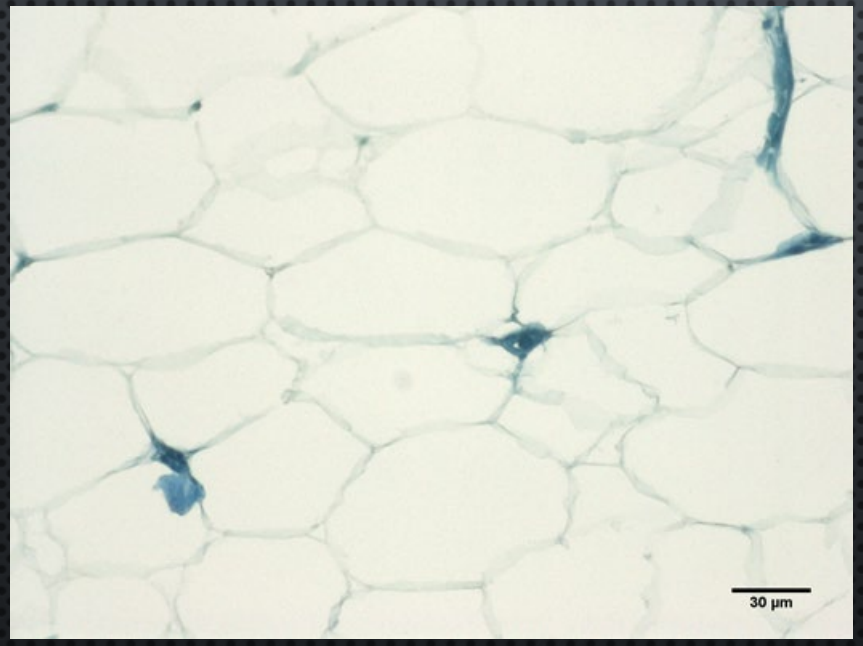

BASELINE

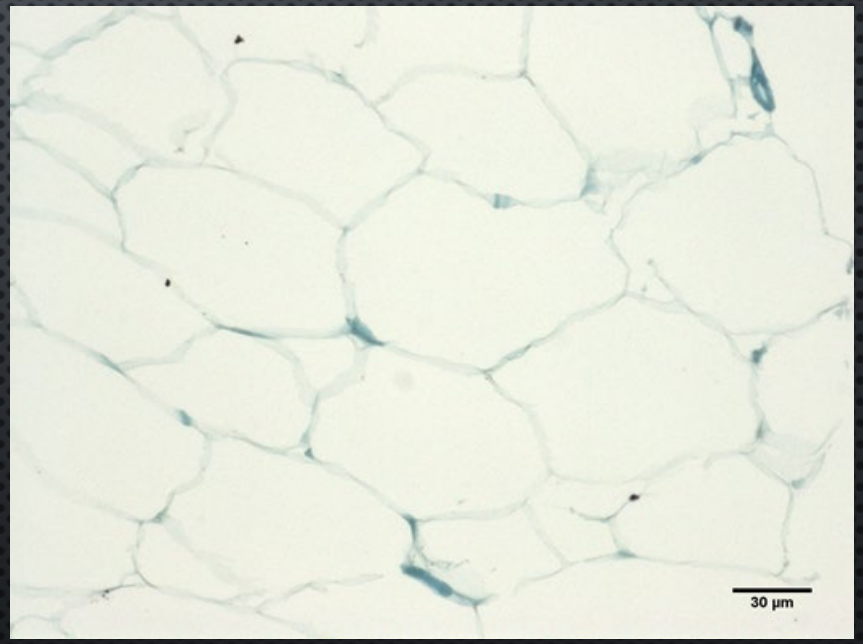

AFTER 1 MONTH

HISTOLOGICAL ANALYSIS OF HUMAN SKIN INDICATES QUANTITATIVE INCREASE OF COLLAGEN AND ELASTIN FIBERS AFTER RADIOFREQUENCY SYNCHRONIZED WITH FACIAL MUSCLE STIMULATION

Karan Lal, M.D., D.O., MS[1] & David Goldberg, M.D.[1]

PRELIMINARY RESULTS

- Visible wrinkle reduction and overall improvement in facial appearance
- Patients reported treatments to be comfortable
- No adverse events monitored

Demonstration of the overall facial improvement

(patient 41 years old) - wrinkle reduction, volume improvement and jawline definition

METHODS

Histological evaluation:

- Skin tissue explants collected by punch biopsy (Ø 3mm)
- Obtained at baseline, 1 month and 3 months post-treatment

- Collagen: **Masson's Trichrome** protocol
- Elastin: **Orcein** protocol

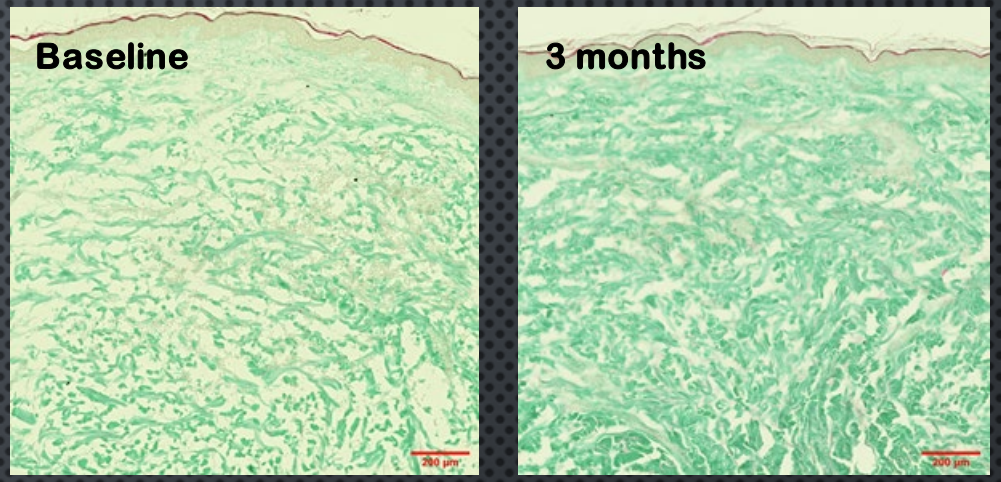

Densification of the collagen fiber network at 3 months post-treatment

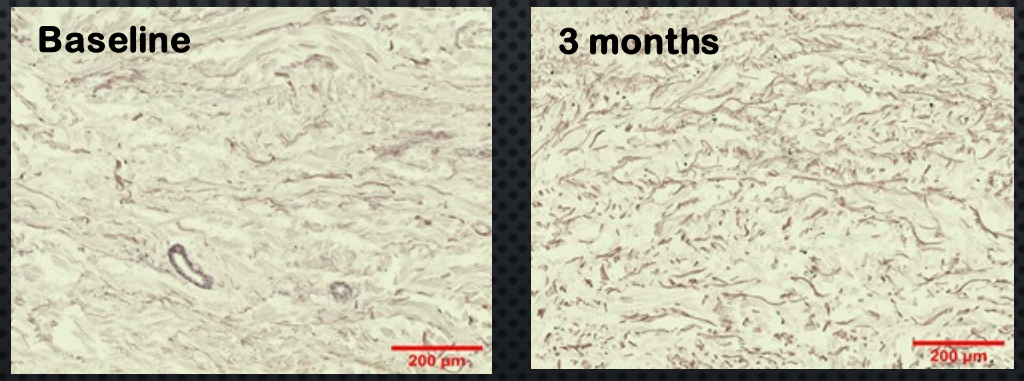

Densification of the elastin fiber network at 3 months post-treatment

Conclusion

- Induces structural changes in human skin tissue

129%

INCREASE IN ELASTIN

27%

INCREASE IN COLLAGEN

BEST DEVICES FOR SKIN TIGHTENING