Great Cases: Psoriasis

Elaine Siegfried, MD

Professor of Pediatrics and Dermatology
Director, Division of Pediatric Dermatology
Cardinal Glennon Children's Hospital
Saint Louis University Health Sciences Center St. Louis, MO

Scalp Psoriasis

Scalp Psoriasis: Focal or Diffuse

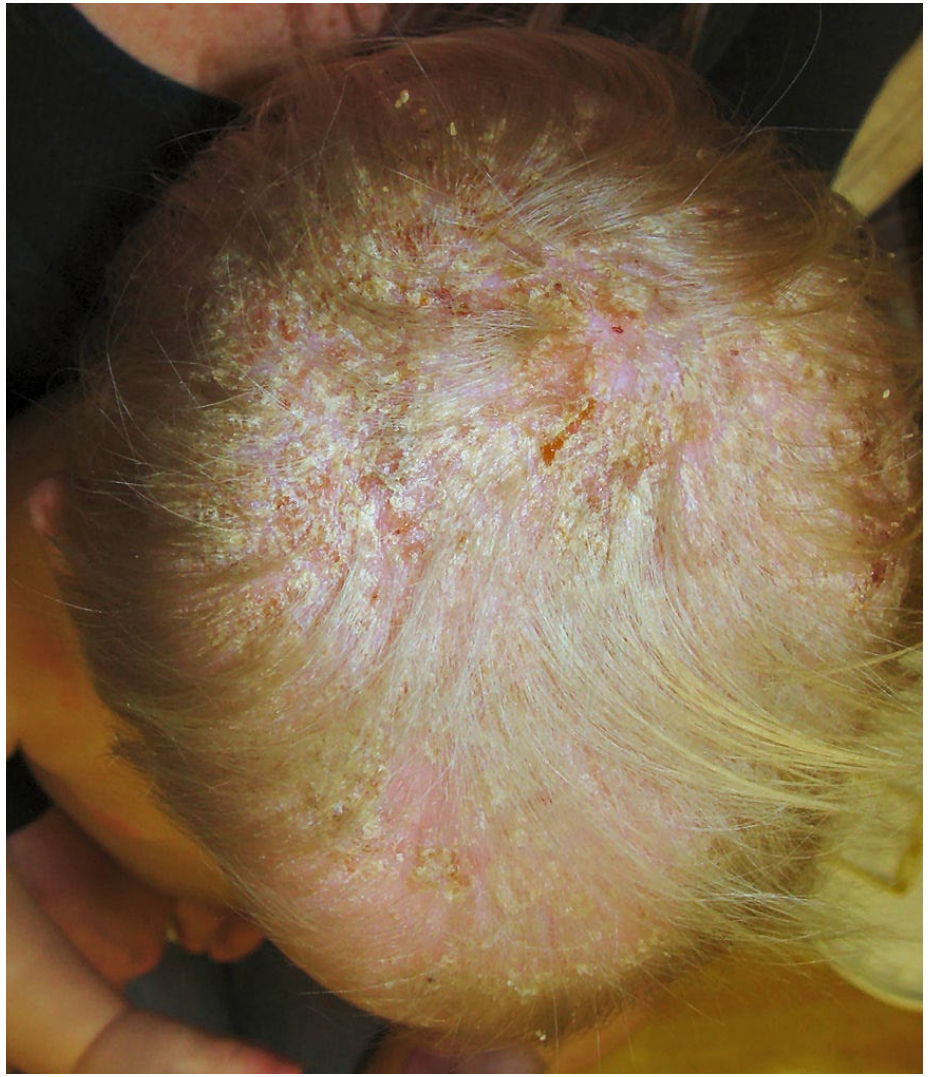

“cradle cap”

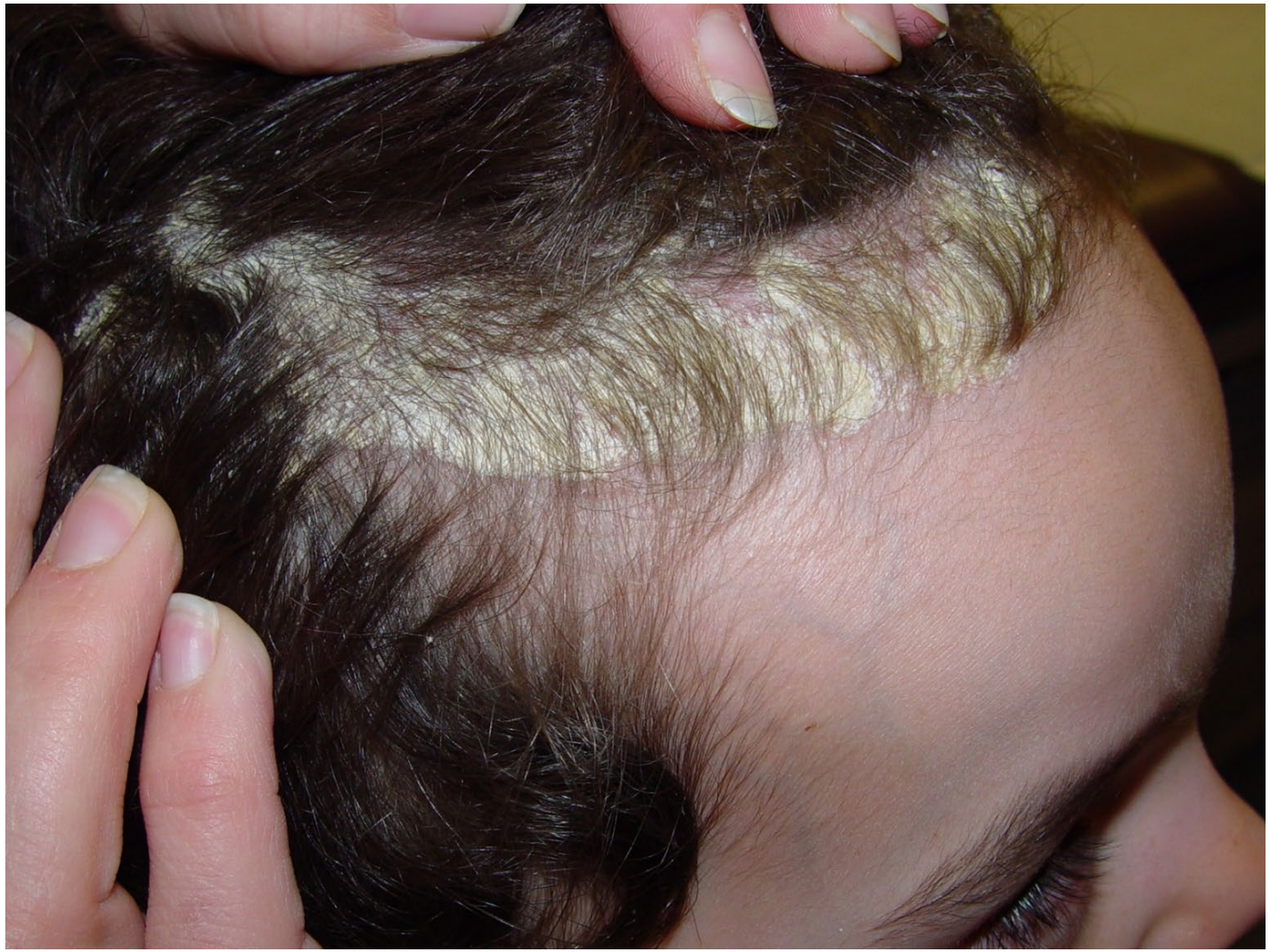

“Pityriasis Amiantacea“ ('amiante’ French for asbestos)

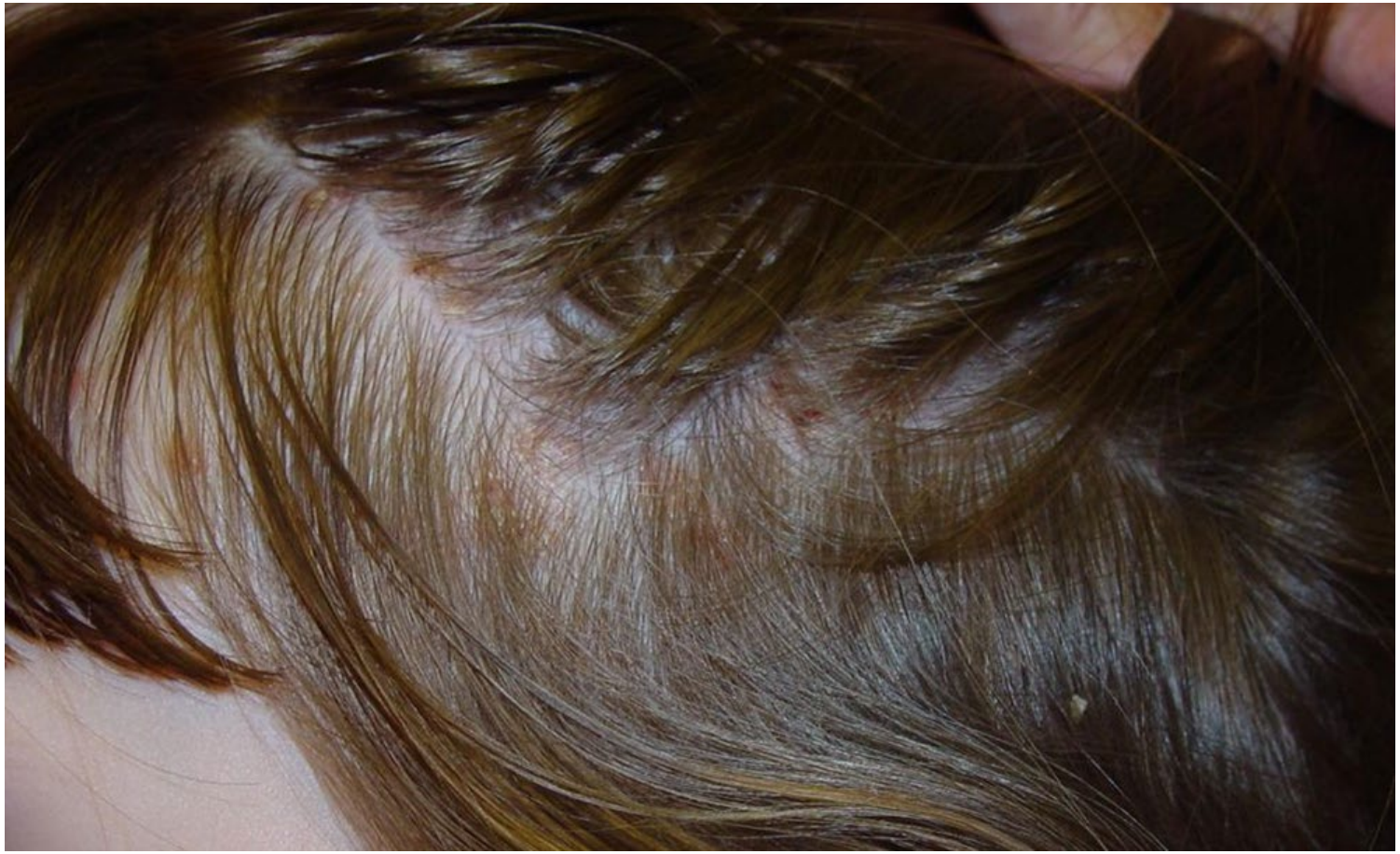

Photo: ESiegfried

Psoriatic Alopecia

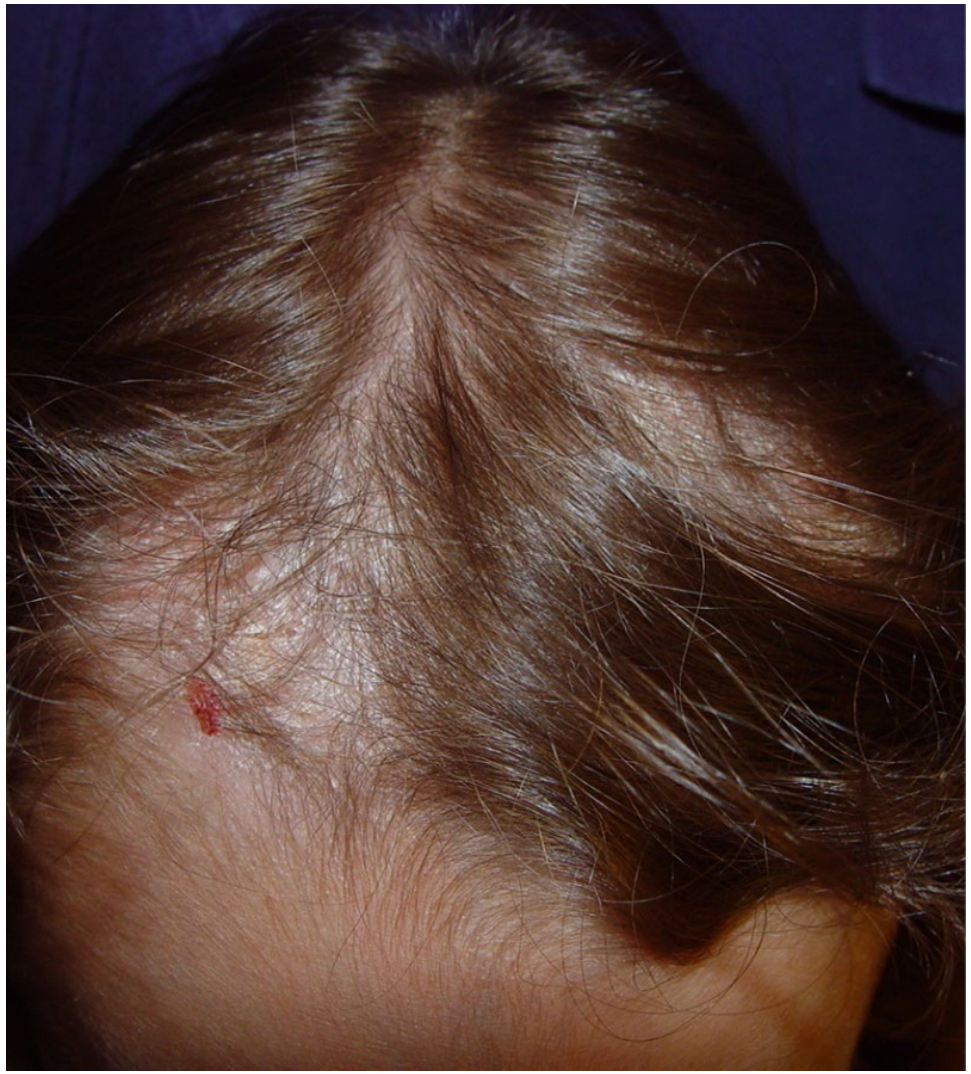

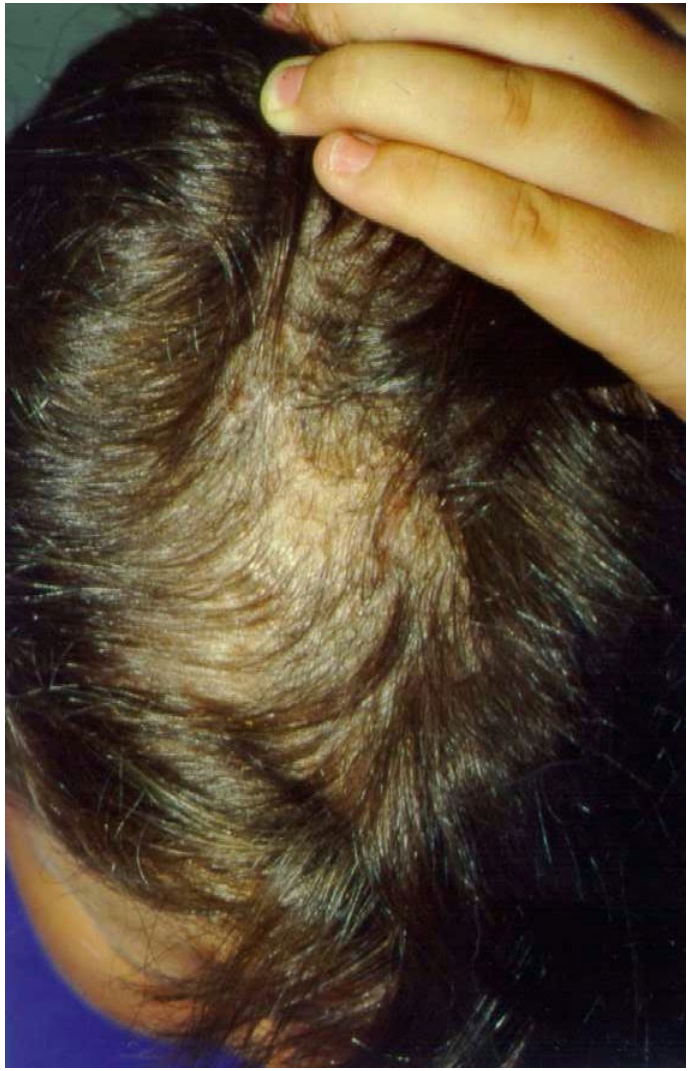

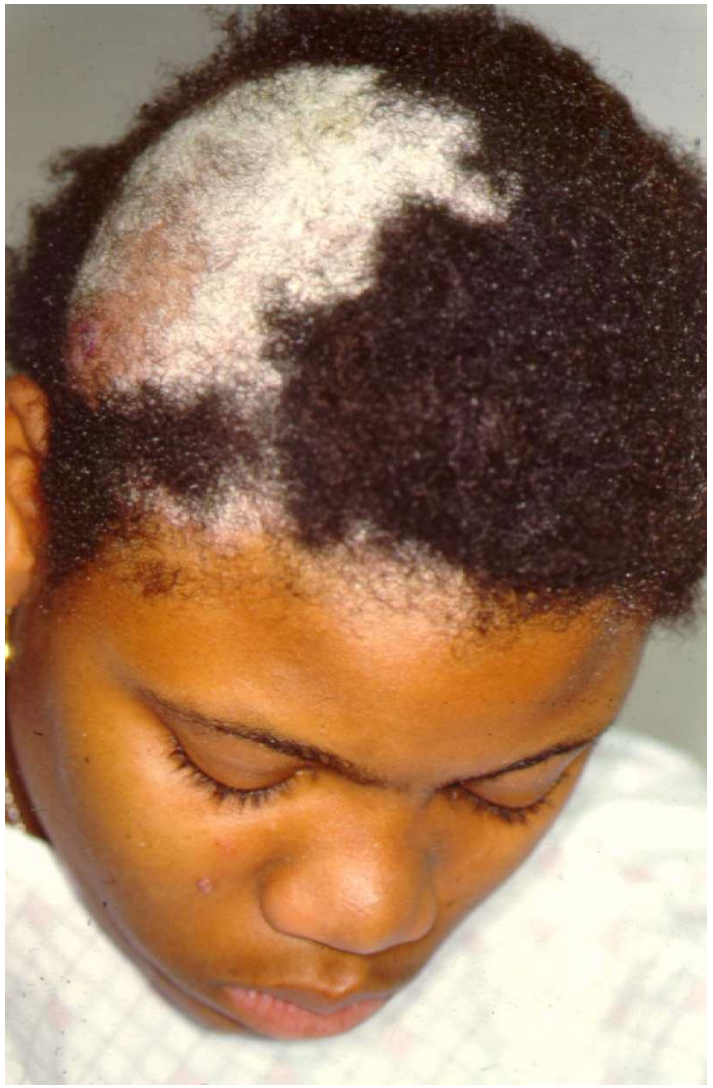

Tinea Capitis Koebernizing Psoriatic Alopecia

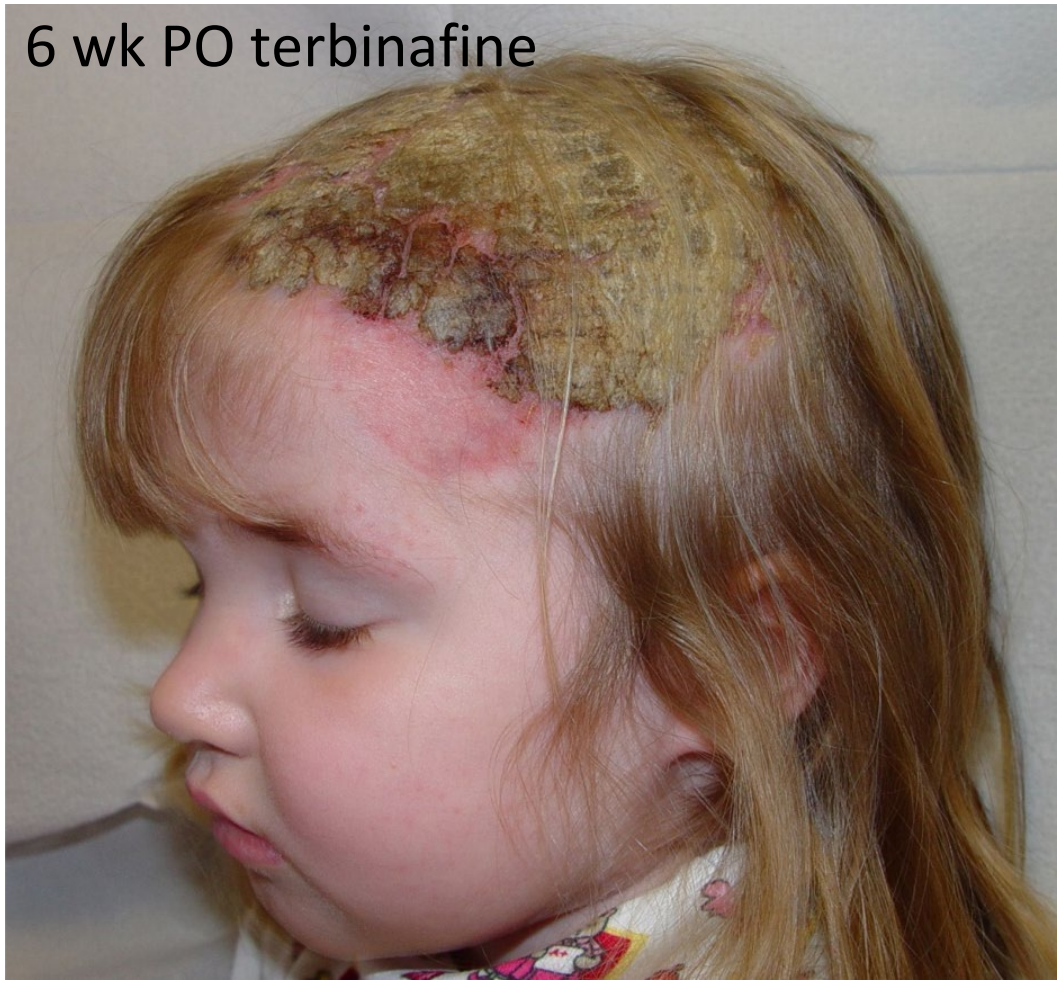

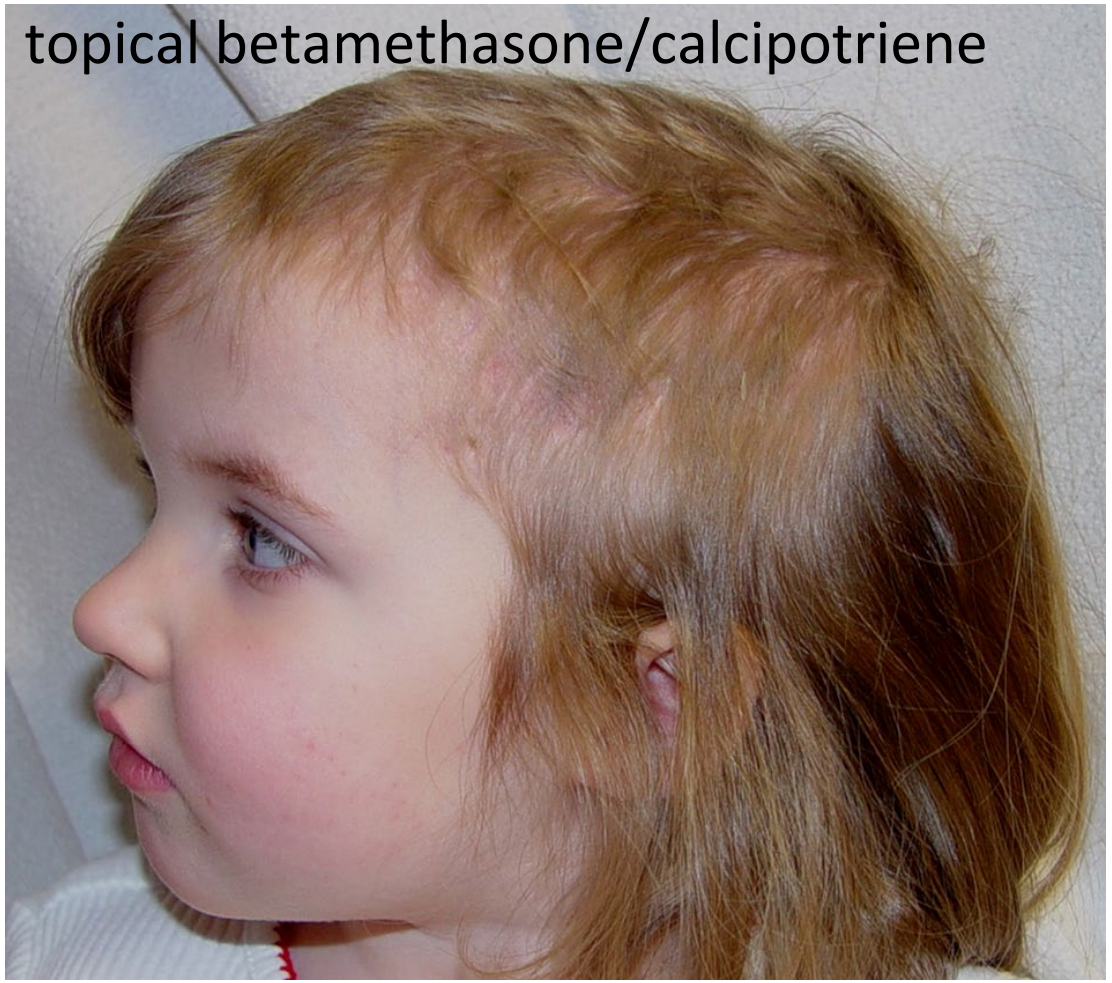

Tinea Corporis Complicating Psoriasis

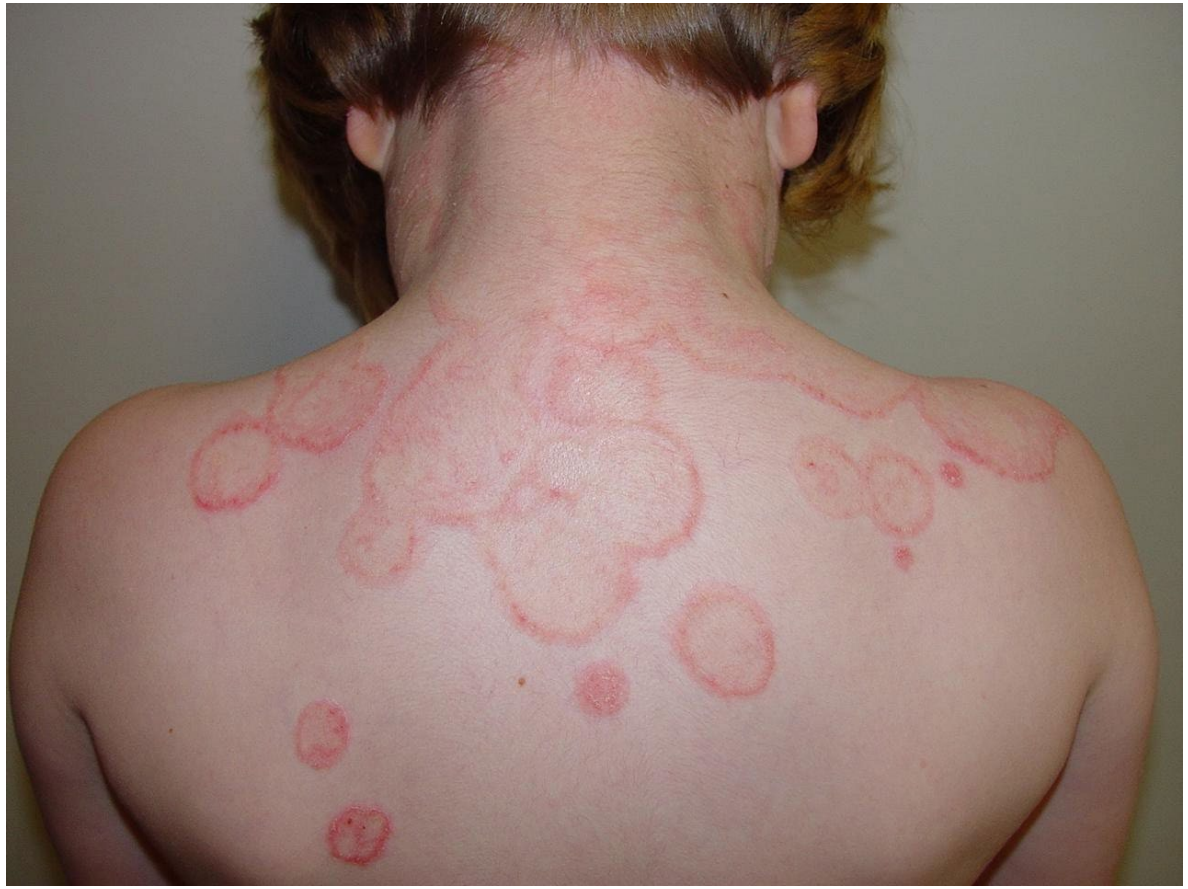

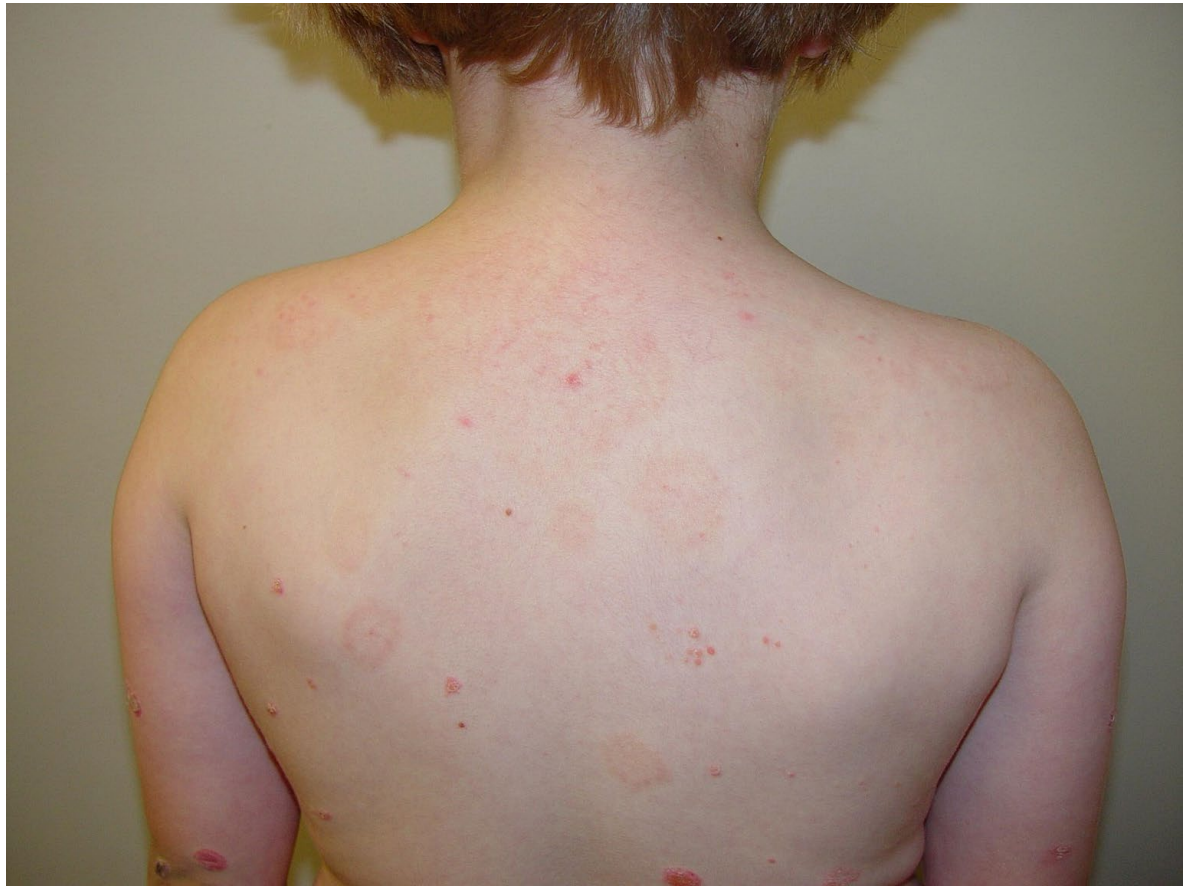

1 mo terbinafine

Treating Scalp Psoriasis

Initial treatment

- "Triple gel"
  - compounded 3-5% LCD, 3-5% salicylic acid and corticosteroid solution or gel
  - readily available
- Combination calcipotriene solution or foam

Maintenance: calcipotriene foam or soln; ketoconazole foam, salicylic acid scalp oil

- Avoid olive oil

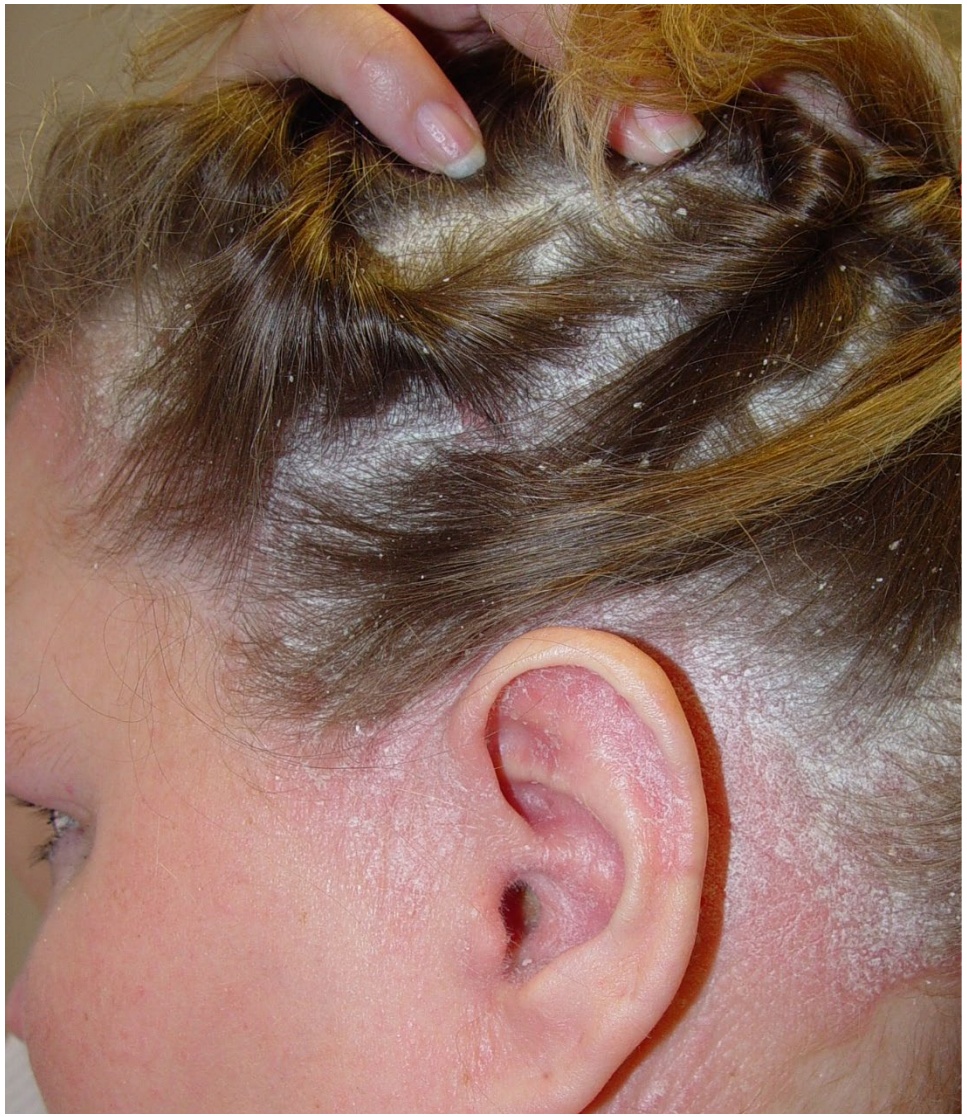

Photo: ESiegfried

Pustular Psoriasis

- US prevalence - 1:10,000, typically adult-onset
- Characterized by episodes of widespread eruptions of painful, sterile pustules)
- Potentially life-threatening

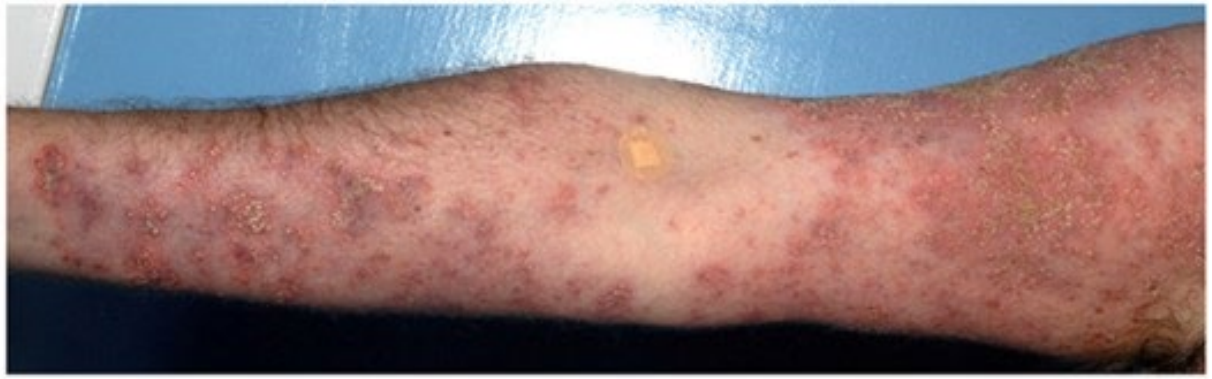

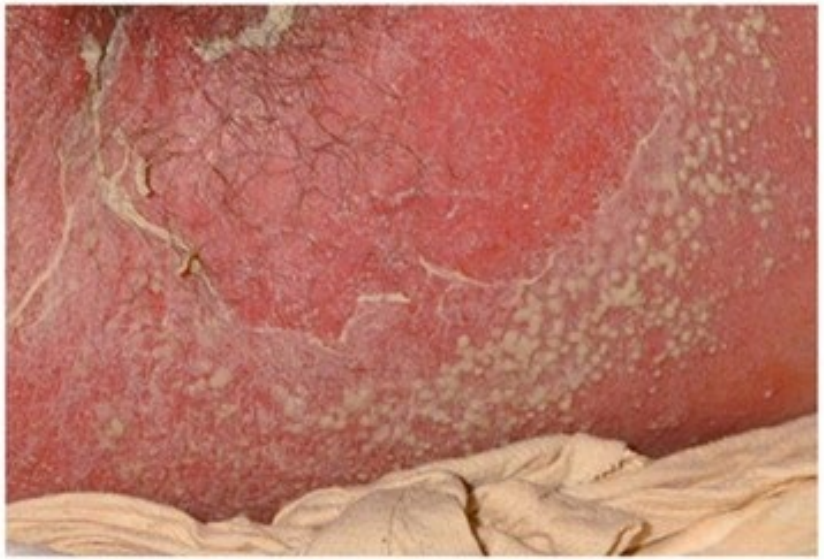

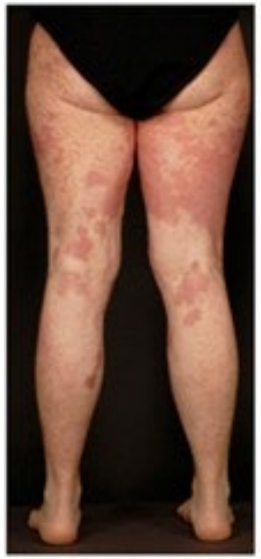

“Acrodermatitis Continua of Hallopeau"

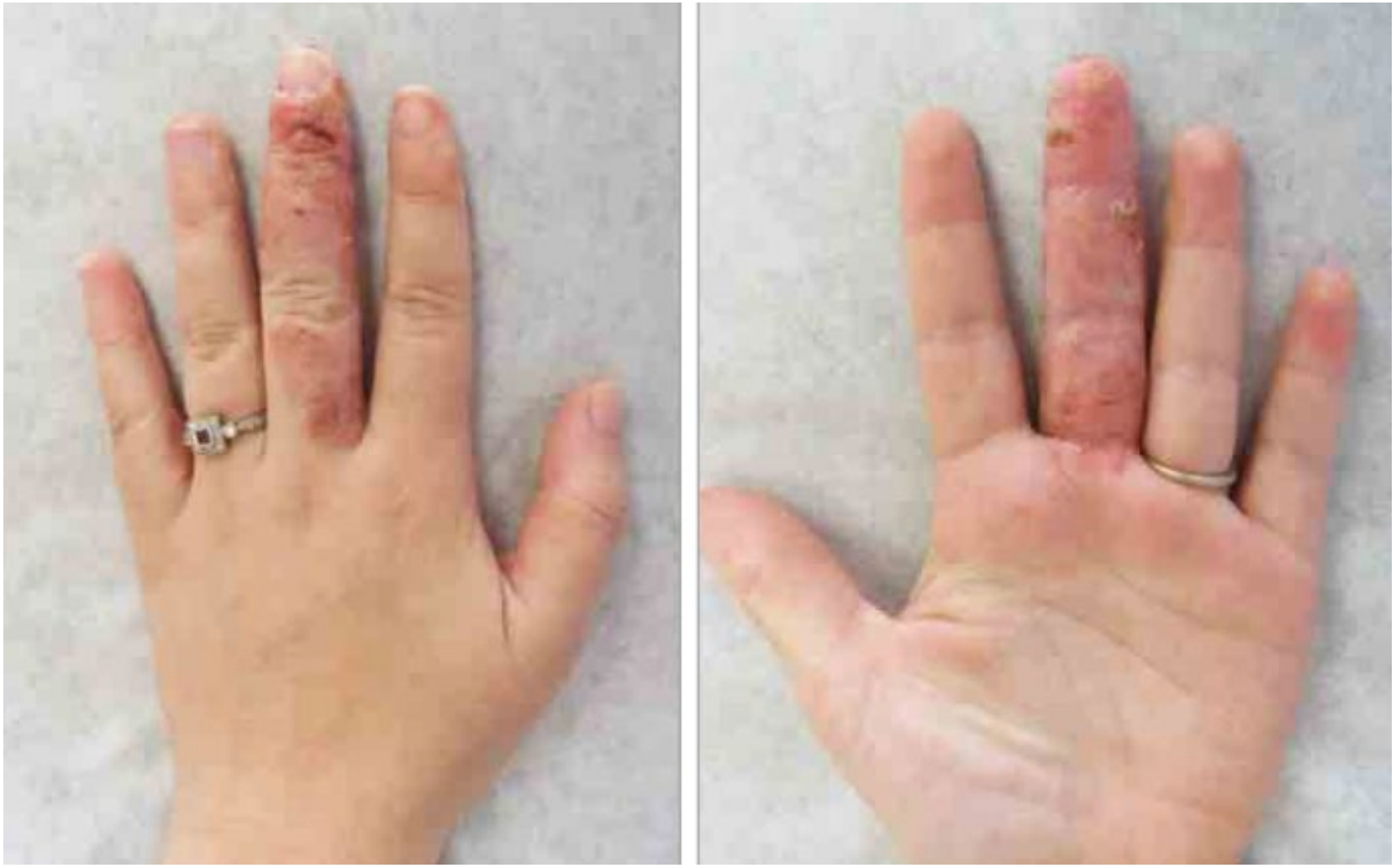

Cymerman RM, Cohen DE. Treatment of Acrodermatitis Continua of Hallopeau with Ustekinumab as Monotherapy. JAMA Dermatol. 2016;152(3):346-8.

Generalized Pustular Psoriasis Insights

- 2011: targeted exome sequencing, 5 unrelated adults with identified IL 36R loss-of-function mutations
- 2021: gene expression compared to psoriasis vulgaris - 28 biopsy specimens, increased expression of IL-1 & IL-36 and decreased expression of IL-17A & IFN-γ
- Highlights IL-1 and IL-36 signaling as a potential therapeutic targets
- Drug-triggered pustular psoriasis has not been well-characterized.
- Pediatric variants have been associated with identified genetic mutations.
- Targeted biologic therapy is emerging.

Onoufriadis A et al. Mutations in IL36RN/IL1F5 are associated with the severe episodic inflammatory skin disease known as generalized pustular psoriasis. Am J Hum Genet. 2011;89(3):432-7.
Iznardo H, Puig L. Exploring the Role of IL-36 Cytokines as a New Target in Psoriatic Disease. Int J Mol Sci. 2021;22(9):4344.

Infantile-Onset Psoriasiform Eruptions with Identified Mutations

- Erythrodermic, plaque and pustular
- Autoinflammatory
- Autosomal recessive, monogenic

CARD14 (Caspase Recruitment Domain Family Member 14)

DITRA (Deficiency of Interleukin-36 Receptor Antagonist)

DIRA (Deficiency of Interleukin-1 Receptor Antagonist)

CARD14-Associated Papulosquamous Eruption (“CAPE”)

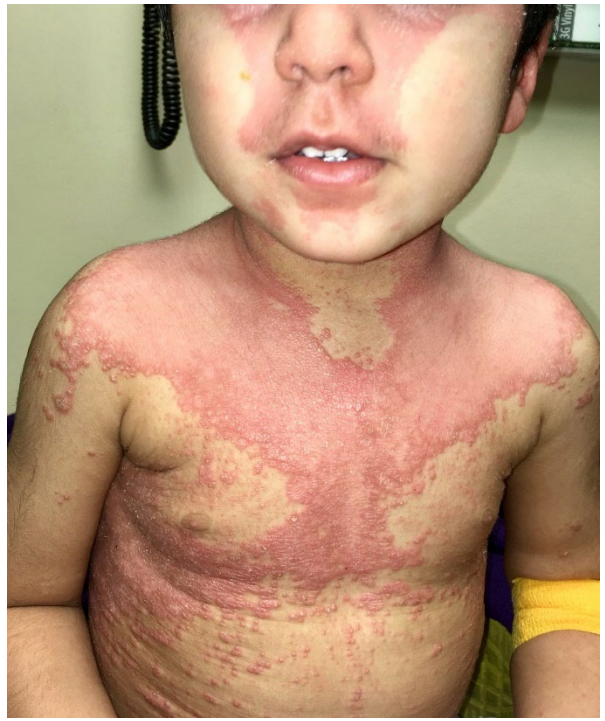

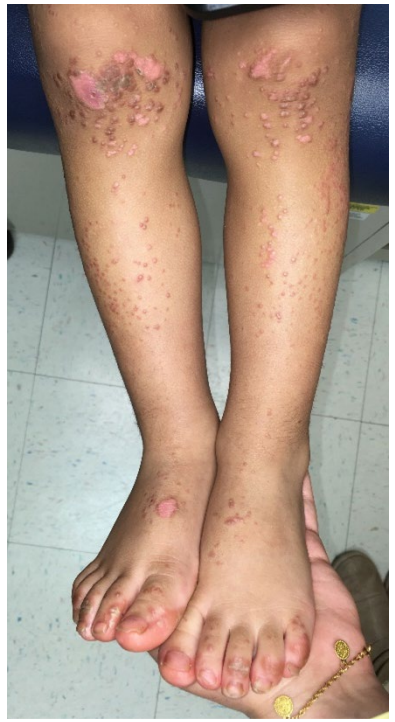

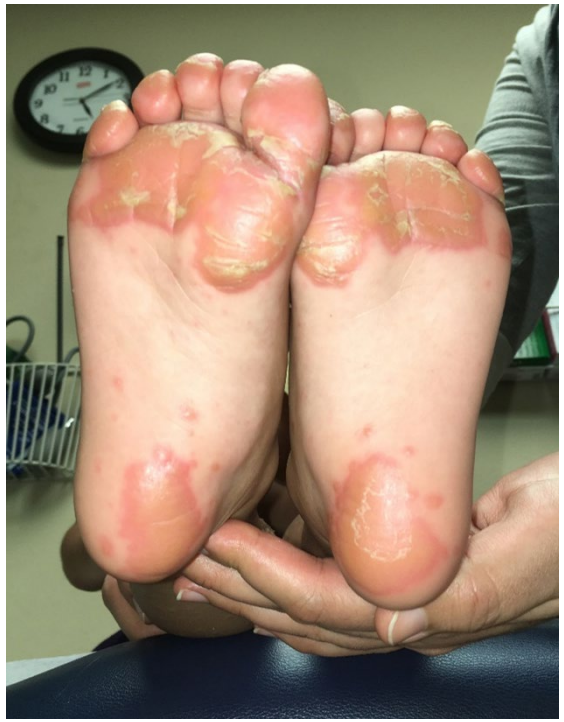

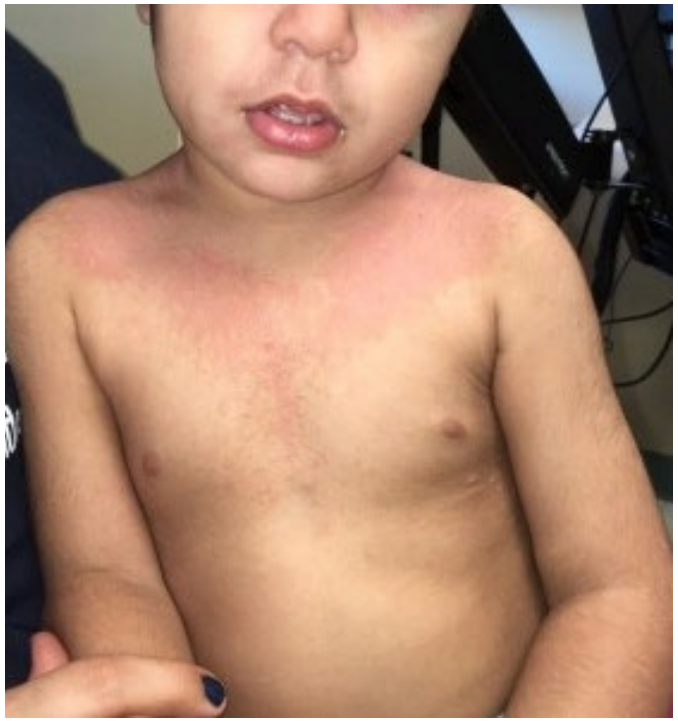

S/P 4 mo acetretin

- early age of onset; prominent facial involvement
- family history of psoriasis or PRP
- minimal response to conventional topical and systemic psoriasis therapies
- ustekinumab has reported efficacy

Craiglow B et al. 2018; JAAD 79(3):487-494.

Generalized Pustular Psoriasis in Infancy
Consider DIRA or DITRA

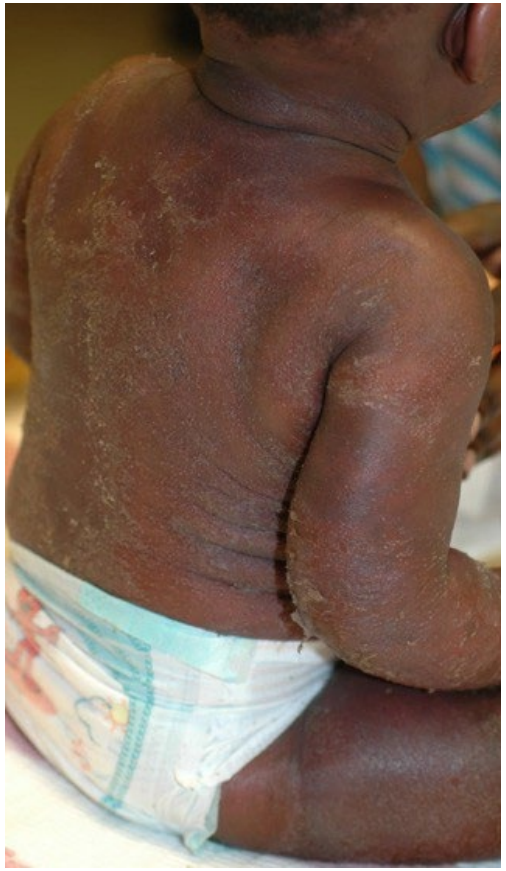
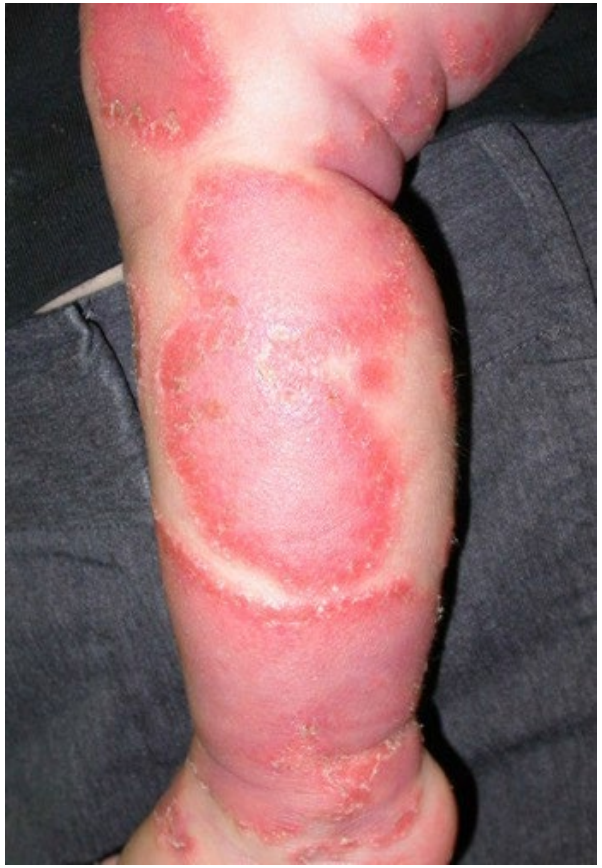
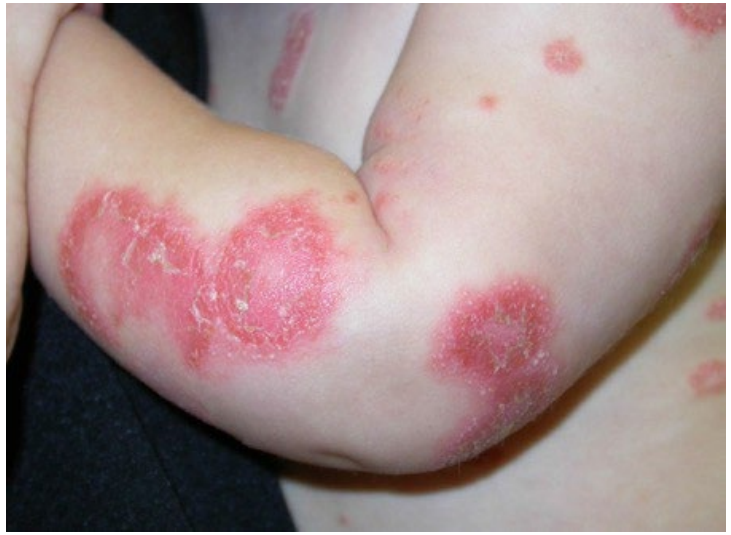

Photos: Neonatal Dermatology Frieden and Eichenfield; Courtesy Brandon Newell, MD.

Cowen EW, Goldbach-Mansky R. DIRA, DITRA, and new insights into pathways of skin inflammation: what's in a name? Arch Dermatol. 2012;148(3):381-4.

DIRA

- Autosomal recessive
- IL1RN mutations
- Early onset generalized pustulosis
- High titer autoantibodies
- Elevated ESR, CRP
- Sterile multifocal osteomyelitis
- Life-threatening
- Reported response to recombinant IL-1RA (anakinra), complicated by anaphylaxis (successfully desensitized)

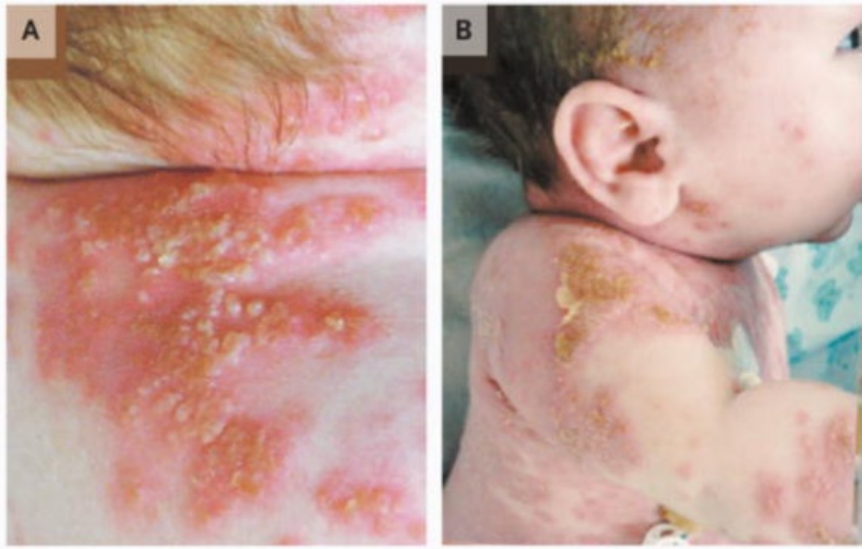

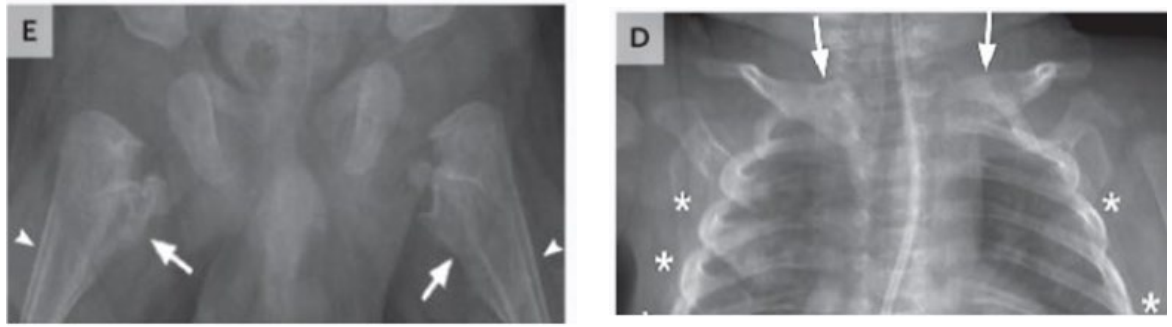

Mendonca LO, et al. Deficiency of Interleukin-1 Receptor Antagonist (DIRA): Report of the First Indian Patient and a Novel Deletion Affecting IL1RN. J Clin Immunol. 2017 Jul;37(5):445.

Aksentijevich I, et al. An autoinflammatory disease with deficiency of the interleukin-1-receptor antagonist. N Engl J Med. 2009;360(23):2426.

DITRA Spectrum

- IL-36 cytokines share partial homology with IL-1.
- IL-36R (aka IL-1 receptor–like 2) is a member of the IL-1 receptor family.
- Inactivating mutations IL-36R antagonist genes lead to unregulated IL-36R signaling
- Associated with autoinflammatory conditions GPP, IBD and inflammatory arthritis
- Anecdotal DITRA GPP response to IL-17 inhibition
- Targeted IL-36R biologics are in development.

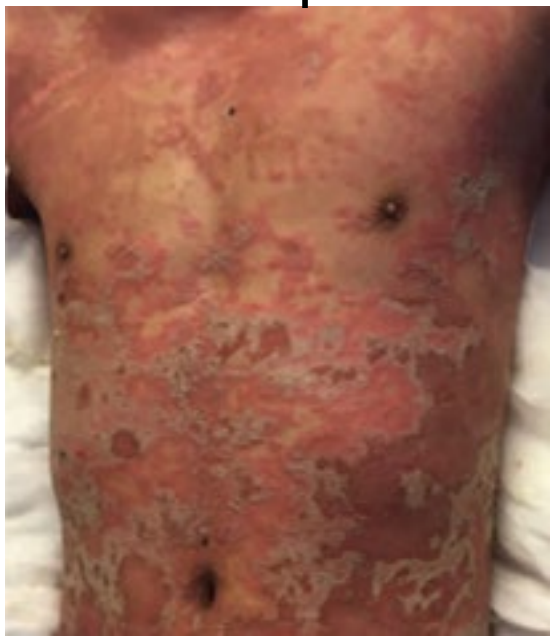

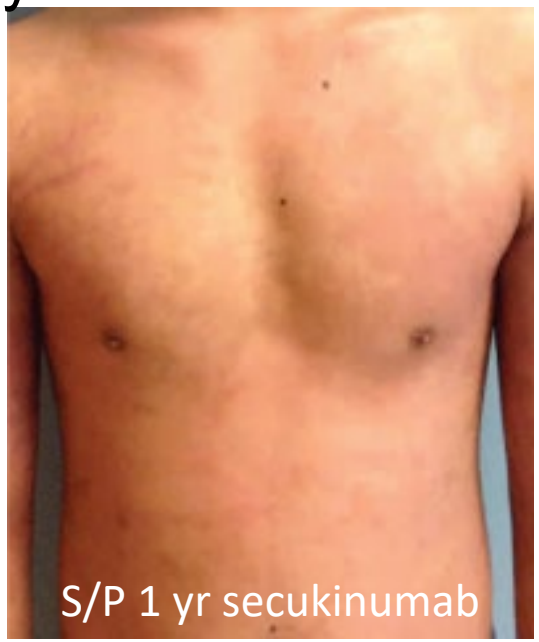

Cordoro KM, Ucmak D, Hitraya-Low M, Rosenblum MD, Liao W. Response to Interleukin (IL)-17 Inhibition in an Adolescent with Severe Manifestations of IL-36 Receptor Antagonist Deficiency (DITRA). JAMA Dermatol. 2017;153(1):106-108.

Walsh PT, Fallon PG. The emergence of the IL-36 cytokine family as novel targets for inflammatory diseases. Ann N Y Acad Sci. 2018;1417(1):23-34.

IL-36R Blockade for Generalized Pustular Psoriasis

- Spesolimab (Spevigo; Boehringer Ingelheim)
  - FDA-approved Sept 2022
  - phase 2b pivotal trial (53 subjects): single IV infusion; 54% active/6% placebo with no visible pustules 1 wk later
  - Most common (≥5%) AEs: asthenia, fatigue, nausea/vomiting, headache, pruritus/prurigo, infusion site hematoma and bruising, UTI
  - SAEs: DRESS, arthritis, drug-related hepatitis
- Imsidolimab (Anaptysbio)

  phase 2 single-arm trial (8 subjects): IV induction, then Q mo SQ monotherapy; #6 (75%) achieved clinical global improvement at wk 4 and 16

Bachelez H et al. Trial of Spesolimab for Generalized Pustular Psoriasis. N Engl J Med. 2021;385(26):2431-2440.

2yo with hx “eczema”

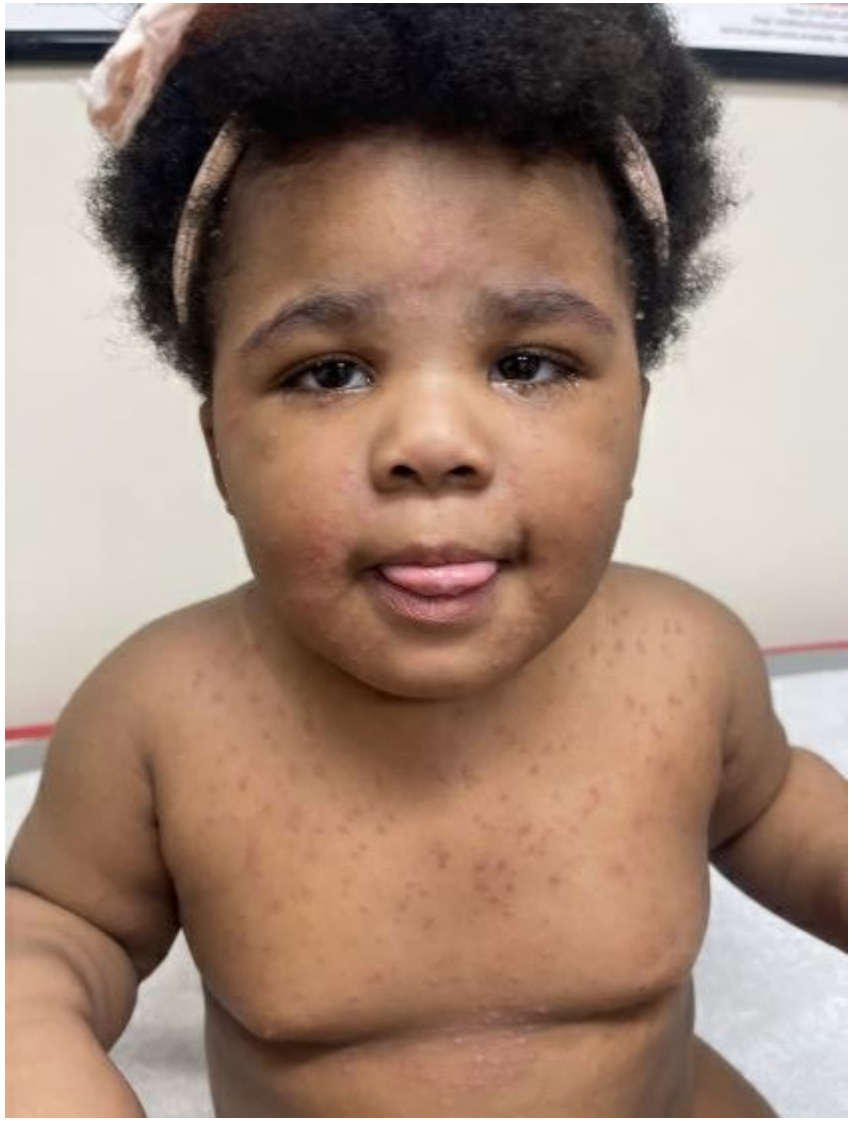

- Multiple ED visits for skin worsening; Rx HC, TMC, Benadryl
- Followed by generalized "skin peeling"+scalp itch; Rx fluocinonide scalp soln (per PCP) with improvement/reoccurrence
- Widespread papules; suspect fungal + ID, **empiric Rx terbinafine**, mometasone, keto shampoo
- No known FH psoriasis

Terbinafine-Triggered Pustular Psoriasis

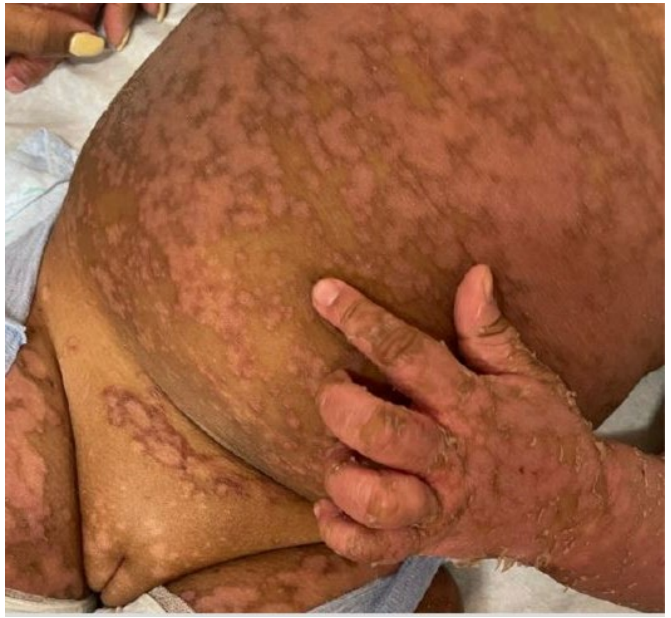

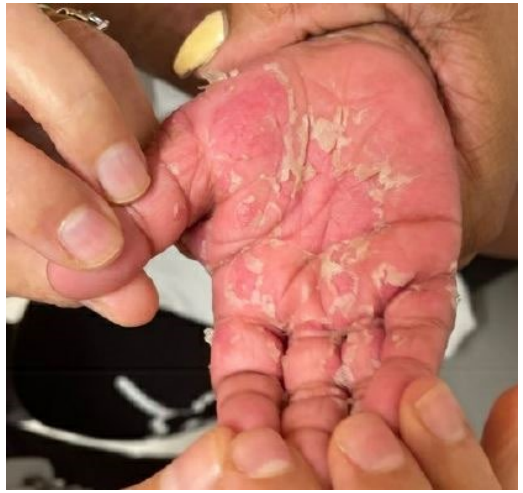

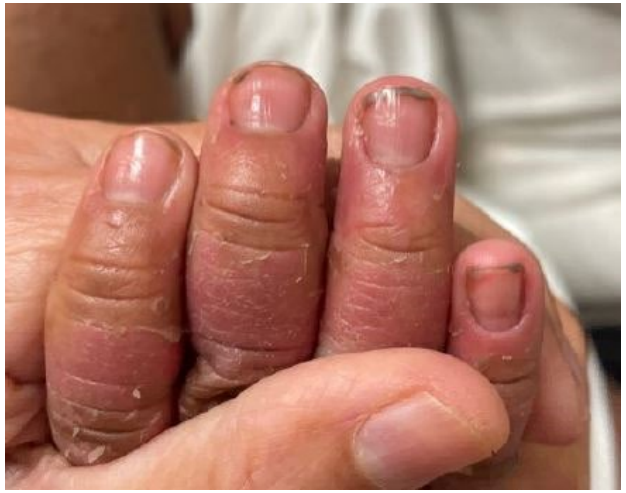

- Worsening with >90% BSA incl scalp, palms, soles with vesiculopustular desquamation
- Punch bx: “psoriasiform dermatitis”, DIF neg, direct admit for intensive skin care
- Invitae*156 gene Autoinflammatory and Autoimmunity Syndromes Panel neg*
- no known FH psoriasis

Sakai H, et al. terbinafine-induced generalized pustular psoriasis in a patient carrying CARD14 mutation. J Dermatol. 2019;46(3):e110.

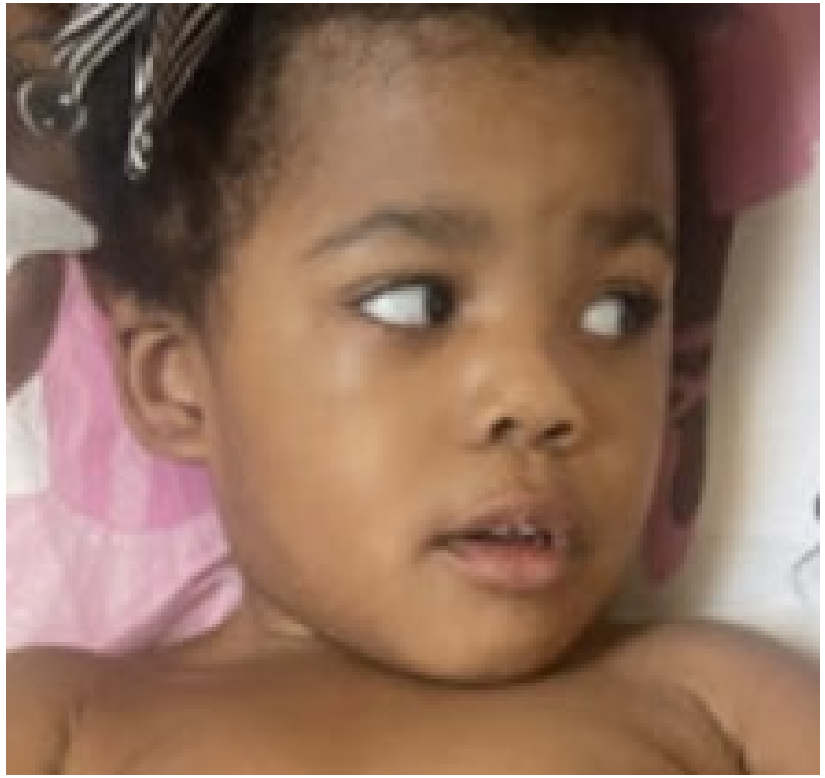

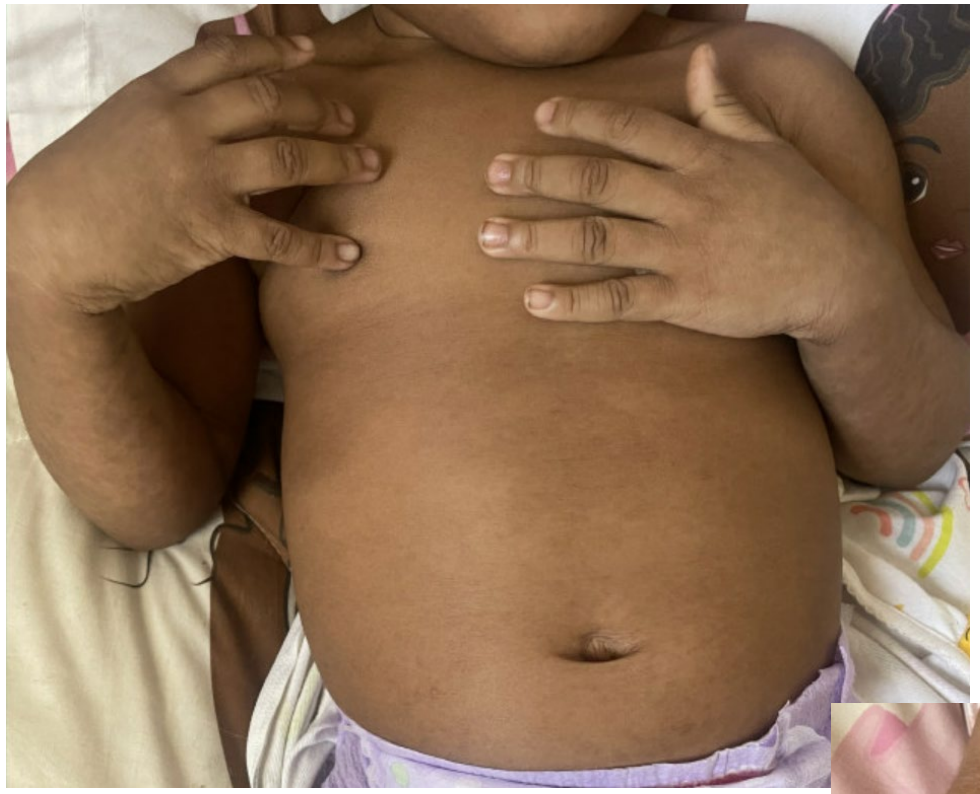

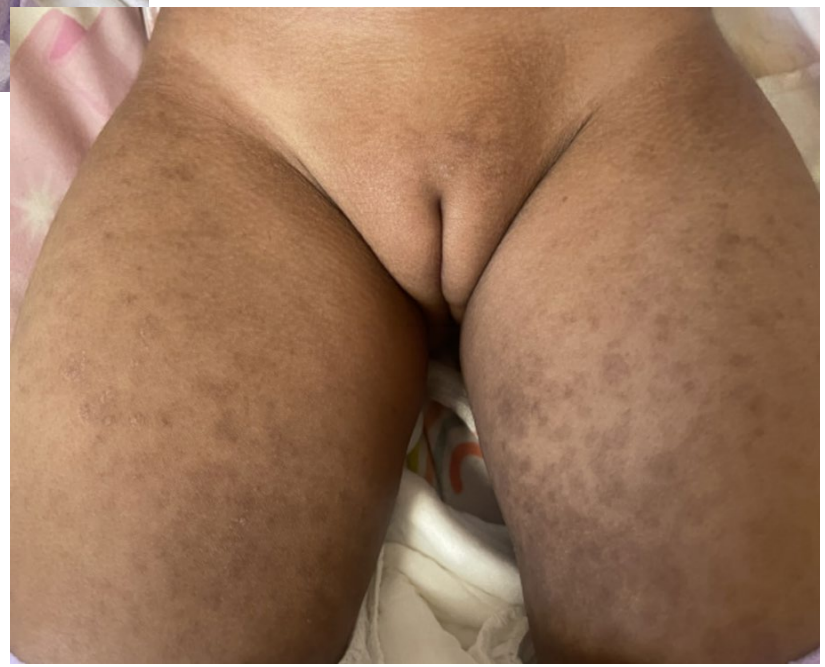

- S/P 1 mo acetretin10mg QOD
- + TCS>Elidel
- 5% BSA