



MASTERS OF
**PEDIATRIC
DERMATOLOGY**
The Latest in PEDIATRIC DERMATOLOGY:
FROM INFANTS TO ADOLESCENTS

Acne in Pediatric Patients with Skin of Color

Candrice R. Heath, MD, FAAP, FAAD
Assistant Professor of Dermatology
Director, Pediatric Dermatology
Lewis Katz School of Medicine, Temple University
Philadelphia, PA



1

Disclosures

Off label use of medications not approved in children may be discussed

Consulting (Advisory Board) Cassiopea



DR. *Candrice*
HEATH

2

Objectives

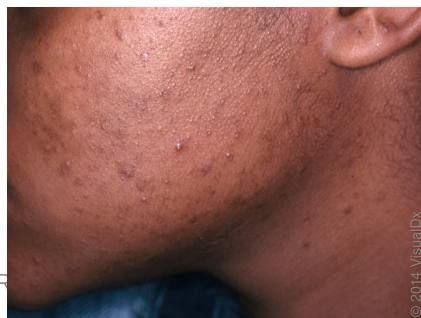- Identify challenges of treating acne in pediatric patients with skin of color
- Develop treatment plans for acne in patients with skin of color



3

Case

- 14 year old
- cc: Dark marks x 3 years, worsening
- PMH: atopic dermatitis
- Using a gentle cleanser and moisturizes with a lotion containing cocoa butter
- Few times a week – facial scrub



DR

© 2014 VisualDx

4

Acne treatments

- Topical Antibiotics
- Oral Antibiotics
- Topical Retinoids
- Oral retinoid
- Topical Anti-androgen
- Oral Anti-androgen



5

Acne treatments

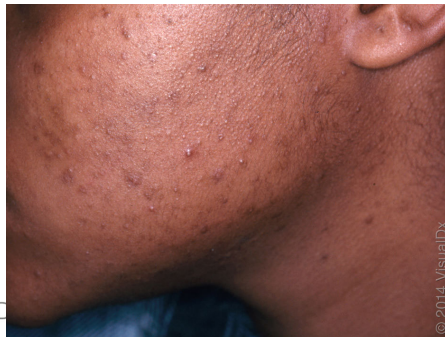Topical Antibiotics	Oral Antibiotics	Topical Retinoids	Oral Retinoids	Topical Anti-androgen	Oral anti-androgen
minocycline 4% foam	sarecycline	trifarotene 0.005% cream tazarotene 0.045% lotion		clascoterone 1% cream	
clindamycin, dapsone	doxycycline, minocycline	tretinoin, adapalene	isotretinoin		spironolactone



6

Case

- Diagnosis: Acne, Post-inflammatory hyperpigmentation
- benzoyl peroxide cleanser
- clindamycin topical
- tretinoin 0.025% nightly
- Gentle cleanser and moisturizer
- Follow up in 2 months



7

You (think you) hit it out of the park



8

Meanwhile in the parking lot...



DR. *Candice*
HEATH

9

Parent and teen's view

- That doctor does not know what they are talking about
- Waste of time
- "All I wanted was something for the dark spots"

DR. *Candice*
HEATH

10

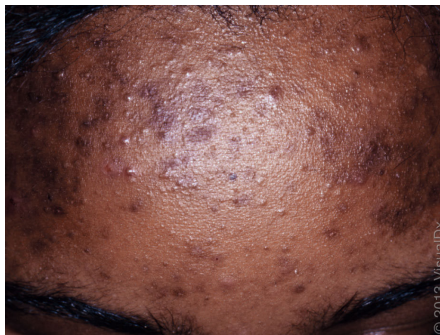
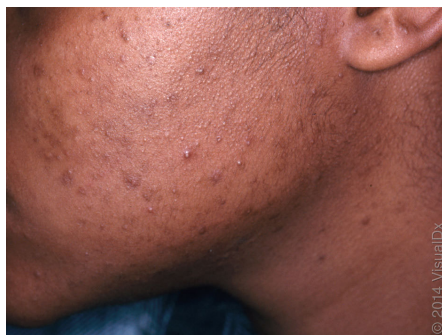Where is the disconnect?

- The PRESENTING complaint = dark marks
- Lay public
 - Scars may = red spots , dark spots/marks, manchas
 - Dermal
(atrophic scars, icepick, boxcar, keloids, hypertrophic)



11

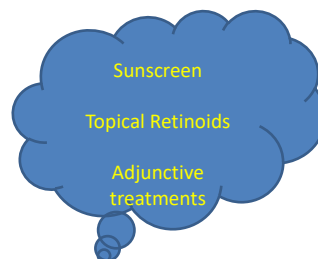
Communicate that you SEE the hyperpigmentation



12

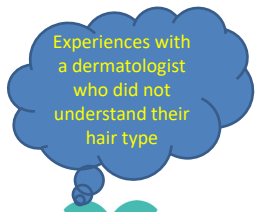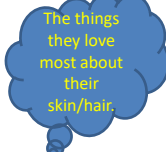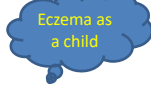
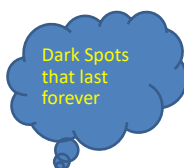Communicate the WHY for each step

- The why
- Set expectations
- Journey
- Partner



13

Emotionally, parents bring their own history of skin concerns to the visit as well.

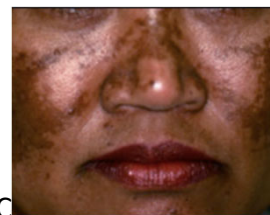

14

Adult QOL Study on Hyperpigmentation

- Highest impact of hyperpigmentation on QOL in:

- women
- those with Post-inflamm. hyperpigmentation
- fewer formal years of education
- higher out of pocket monthly spending on skin-enhancing products

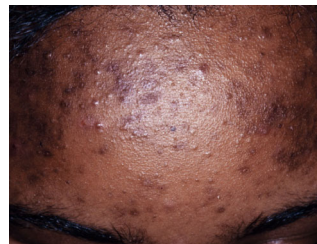
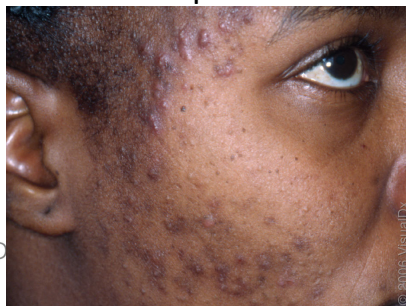
LEADING chief complaint in SOC

15

Teenagers with severe acne, acne scarring, post-inflammatory hyperpigmentation

- Consider isotretinoin and start discussions
 - Complete before teen leaves for college



Heath C. Managing PIH in Pediatric Patients with Skin of Color. 2019; Alexis et al. Treating Acne in patients with SOC. 2018.

16

Beware: Retinoid Dermatitis

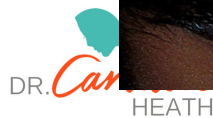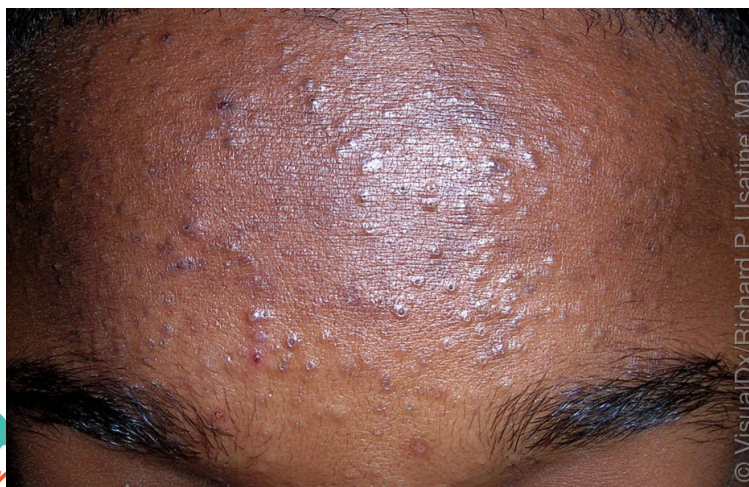- Avoid causing additional inflammation
 - PIH
- Skin of Color – Atopic dermatitis persistence
- Explore different medication vehicles

Ask about mail order products



17

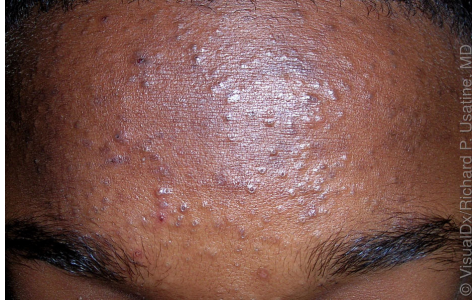Ask about Hair and Skin Care practices



© VisualDx/Richard P. Usatine, MD

18

Pomade Acne



- South Asian (Indian) teen recently moved to the US
- Applies oil to hair daily
- Oils may include:
 - Coconut oil
 - Amla oil
 - Eclipta alba (from sunflower family)
- Oils → comedogenic



Gupta et. A. Dermatoses due to Indian cultural practices. 2015. Ind J Dermatol

19

Masters of Pediatric Dermatology

Acne in Pediatric Patients with Skin of Color

<https://us02.whatsapp.com/data/8190583348681995933186>

Candrice R. Heath, MD, FAAP, FAAD

Assistant Professor of Dermatology

Director, Pediatric Dermatology

Lewis Katz School of Medicine, Temple University

Philadelphia, PA



@DrCandriceHeath

20